

A Supplement to:

The  
Journal  
of **Foot &  
Ankle  
Surgery**



An official publication of the  
American College of  
Foot and Ankle Surgeons

# DIABETIC FOOT DISORDERS

## A CLINICAL PRACTICE GUIDELINE

Development and publication of this Clinical Practice  
Guideline was made possible by an Educational Grant  
Co-Sponsored by Johnson & Johnson Wound Management,  
a division of ETHICON, INC. and KCI USA, Inc.



---

*Supplement to:*

The  
Journal  
of **Foot &  
Ankle  
Surgery**

---

# **DIABETIC FOOT DISORDERS:** A CLINICAL PRACTICE GUIDELINE (2006 revision)

Robert G. Frykberg, DPM, MPH,<sup>1</sup> Thomas Zgonis, DPM,<sup>2</sup> David G. Armstrong, DPM, PhD,<sup>3</sup> Vickie R. Driver, DPM, MS<sup>4</sup> John M. Giurini, DPM,<sup>5</sup> Steven R. Kravitz, DPM,<sup>6</sup> Adam S. Landsman, DPM, PhD,<sup>7</sup> Lawrence A. Lavery, DPM, MPH,<sup>8</sup> J. Christopher Moore, DPM,<sup>9</sup> John M. Schuberth, DPM,<sup>10</sup> Dane K. Wukich, MD,<sup>11</sup> Charles Andersen, MD,<sup>12</sup> and John V. Vanore, DPM<sup>13</sup>

Address correspondence to: Robert G. Frykberg, DPM, MPH, Chief, Podiatric Surgery, Carl T. Hayden VA Medical Center, Phoenix, AZ 85012. Email: robert.frykberg@med.va.gov

<sup>1</sup>Chair, Diabetes Panel, Phoenix, AZ; <sup>2</sup> San Antonio, TX; <sup>3</sup> North Chicago, IL; <sup>4</sup> Evanston, IL; <sup>5</sup> Boston, MA; <sup>6</sup> Richboro, PA; <sup>7</sup> Boston, MA; <sup>8</sup> Georgetown, TX; <sup>9</sup> Ashville, NC; <sup>10</sup> San Francisco, CA; <sup>11</sup> Pittsburgh, PA; <sup>12</sup> Seattle, WA; <sup>13</sup> Chair, Clinical Practice Guidelines Core Committee, Gadsden, AL

# DIABETIC FOOT DISORDERS: A CLINICAL PRACTICE GUIDELINE (2006 revision)

**ABSTRACT:** *The prevalence of diabetes mellitus is growing at epidemic proportions in the United States and worldwide. Most alarming is the steady increase in type 2 diabetes, especially among young and obese people. An estimated 7% of the US population has diabetes, and because of the increased longevity of this population, diabetes-associated complications are expected to rise in prevalence.*

*Foot ulcerations, infections, Charcot neuroarthropathy, and peripheral arterial disease frequently result in gangrene and lower limb amputation. Consequently, foot disorders are leading causes of hospitalization for persons with diabetes and account for billion-dollar expenditures annually in the US. Although not all foot complications can be prevented, dramatic reductions in frequency have been achieved by taking a multidisciplinary approach to patient management. Using this concept, the authors present a clinical practice guideline for diabetic foot disorders based on currently available evidence, committee consensus, and current clinical practice. The pathophysiology and treatment of diabetic foot ulcers, infections, and the diabetic Charcot foot are reviewed. While these guidelines cannot and should not dictate the care of all affected patients, they provide evidence-based guidance for general patterns of practice. If these concepts are embraced and incorporated into patient management protocols, a major reduction in diabetic limb amputations is certainly an attainable goal.*

This clinical practice guideline (CPG) is based on the consensus of current clinical practice and review of the clinical literature. This guideline was developed by the Clinical Practice Guideline Diabetes Panel of the American College of Foot and Ankle Surgeons.

## INTRODUCTION

The prevalence of diabetes mellitus is growing at epidemic proportions in the United States and worldwide (1). Most alarming is the steady increase in type 2 diabetes, especially among young and obese persons. An estimated 7% of Americans are afflicted with diabetes, and with the longevity of this population increasing, the prevalence of diabetes-related complications will continue to rise.

Foot disorders are a major source of morbidity and a leading cause of hospitalization for persons with diabetes. Ulceration, infection, gangrene, and amputation are significant complications of the disease, estimated to cost billions of dollars each year. Charcot foot, which of itself can lead to limb-threatening disorders, is another serious complication of long-standing diabetes. In addition to improving the management of ulcers—the leading precursor to lower extremity amputation in diabetic patients (2)—clinicians

must determine how to more effectively *prevent* ulceration. Although not all diabetic foot disorders can be prevented, it is possible to effect dramatic reductions in their incidence and morbidity through appropriate evidence-based prevention and management protocols.

Taking a multidisciplinary approach to diabetic foot disorders, many centers from around the world have noted consistent improvement in limb salvage rates. With this premise as our central theme, the authors present this clinical practice guideline based on currently available evidence. Three major pedal complications of diabetes are reviewed: diabetic foot ulcers, diabetic foot infections, and the diabetic Charcot foot. These guidelines are intended to provide evidence-based guidance for general patterns of practice and do not necessarily dictate the care of a particular patient.

## EPIDEMIOLOGY OF DIABETIC FOOT DISORDERS

Diabetes is one of the foremost causes of death in many countries and a leading cause of blindness, renal failure, and nontraumatic amputation. Global prevalence of diabetes in 2003 was estimated to be 194 million (3). By 2030, this figure is predicted to rise to 366 million due to longer life expectancy and changing dietary habits (4).

The estimated incidence of diabetes in the US exceeds 1.5 million new cases annually, with an overall prevalence of 20.8 million people or 7% of the nation's population (5). An estimated 14.6 million persons are currently diagnosed with the disease, while an additional 6.2 million people who have diabetes remain undiagnosed; this represents a sixfold increase in the number of persons with diabetes over the past four decades (6). A higher incidence of diabetes occurs among non-Hispanic blacks, Hispanic/Latino Americans, and Native Americans compared with non-Hispanic whites (7). Diagnosed diabetes is most prevalent in middle-aged and elderly populations, with the highest rates occurring in persons aged 65 years and older (8-10). As the sixth leading cause of death in the US, diabetes contributes to more than 224,000 deaths per year (5).

**Table 1 Classification of Diabetes Mellitus \***

Type 1 diabetes - absolute insulin deficiency
Type 2 diabetes - insulin resistant +/- insulin deficiency
Other types - genetic defects of $\beta$ -cell function or insulin action
endocrinopathies
drug or chemical
infections
Gestational diabetes

\* adapted from: *Therapy for Diabetes Mellitus and Related Disorders*, 3rd edition, American Diabetes Association, 1998.

Four categories of diabetes are recognized (Table 1). Type 1, formerly insulin-dependent diabetes mellitus (IDDM), is an autoimmune disease affecting the pancreas. Individuals with type 1 diabetes are prone to ketosis and unable to produce endogenous insulin. Type 2, formerly non-insulin dependent diabetes mellitus (NIDDM), accounts for 90% to 95% of cases diagnosed. Type 2 diabetes is characterized by hyperglycemia in the presence of hyperinsulinemia due to peripheral insulin resistance. Gestational as well as genetic defects and endocrinopathies are recognized as other types of diabetes (11). Diabetes is associated with numerous complications related to microvascular, macrovascular, and metabolic etiologies. These include cerebrovascular, cardiovascular, and peripheral arterial disease; retinopathy; neuropathy; and nephropathy. Currently, cardiovascular complications are the most common cause of premature death

among patients with diabetes (9, 12). Rates of heart disease and stroke are 2 to 4 times higher among diabetic adults compared with nondiabetic adults, accounting for about 65% of deaths in people with diabetes (5). Estimated total (direct and indirect) annual expenditures for diabetes management in 2002 was \$132 billion, representing 1 of every 10 health care dollars spent in the US (13).

One of the most common complications of diabetes in the lower extremity is the diabetic foot ulcer. An estimated 15% of patients with diabetes will develop a lower extremity ulcer during the course of their disease (14-17). Several population-based studies indicate a 0.5% to 3% annual cumulative incidence of diabetic foot ulcers (18-21). According to one large British study of neuropathic patients, the 1-year incidence of initial foot ulcer was 7% (22). The prevalence of foot ulcers reported for a variety of populations ranges from 2% to 10% (16, 18, 22, 23). Neuropathy, deformity, high plantar pressure, poor glucose control, duration of diabetes, and male gender are all contributory factors for foot ulceration (see the following section: "Risk for Ulceration") (24-27). National hospital discharge data indicate that the average hospital length of stay (LOS) for diabetic patients with ulcer diagnoses was 59% longer than for diabetic patients without ulcers (16). While 7% to 20% of patients with foot ulcers will subsequently require an amputation, foot ulceration is the precursor to approximately 85% of lower extremity amputations in persons with diabetes (28-31).

Diabetes continues to be the most common underlying cause of nontraumatic lower extremity amputations (LEAs) in the US and Europe (1, 32). More than 60% of LEAs in the US occur in people with diabetes, averaging 82,000 per year (5, 10). While the number of diabetes-related hospital discharges has progressively increased from 33,000 in 1980 to 84,000 in 1997, this number seems to have leveled off during the present decade. In 2002, there were 82,000 diabetes-related LEA discharges, accounting for 911,000 days of hospital stay with an average LOS of 11.2 days (10). The age-adjusted rate of amputation for that year was 5.2 per 1,000 persons with diabetes, a notable decrease from the highest rate of 8.1 per 1,000 in 1996.

In terms of level of diabetes-related lower limb amputations, toe amputations comprise the majority of procedures. The age-adjusted LEA rate in 2002 among persons with diabetes was highest for toe LEA (2.6 per 1,000 persons), followed by below-knee LEA (1.6 per 1,000 persons). For foot LEA and above-knee LEA, the age-adjusted rate was 0.8 per 1,000 persons. These trends in amputation level have essentially remained the same since 1993 (10). Generally, the LEA rate is 15 to 40 times higher in the diabetic versus

nondiabetic populations, and the rate is at least 50% higher in men versus women (8, 10, 12, 33). In 2002, the age-adjusted LEA rate among men was 7.0 per 1,000 persons with diabetes compared with the rate among women reported at 3.3 per 1000 persons with diabetes (10).

Several ethnic differences occur in the frequency of diabetes-related amputations. Mexican (Hispanic) Americans, Native Americans, and African Americans each have at least a 1.5- to 2-fold greater risk for diabetes-related amputation than age-matched diabetic Caucasians (8, 10, 16, 17, 34, 35). When LEA risk is compared between diabetic and nondiabetic populations worldwide, it is apparent that both diabetes and ethnicity have profound implications on rates of lower limb amputation (1, 17).

Survival rates after amputation are generally lower for diabetic versus nondiabetic patients (16, 17, 29). The 3- and 5-year survival rates are about 50% and 40%, respectively, with cardiovascular disease being the major cause of death (8). Although mortality rates following major amputation are high among both diabetic and nondiabetic patients, a recent study reported no significant difference between these two populations. The mean survival was approximately 6.5 years, with a 68% mortality after 9 years regardless of diabetes status (36). An earlier study from Sweden reported a 5-year mortality rate of 68% after lower limb amputation, with survival rates lower among patients who underwent higher levels of amputation (29). Similar trends were found in a review of amputations within the Veterans Affairs system, but worse survival outcomes were observed for older patients, those with renal disease, and those with peripheral arterial disease (37). Researchers have reported a 50% incidence of serious contralateral foot lesion (ie, ulcer) following an LEA, and a 50% incidence of contralateral amputation within 2 to 5 years of an LEA (16, 29).

Total (direct and indirect) annual health care costs for persons with diabetes were estimated to be \$132 billion in 2002. Direct medical expenditures, including hospitalization, medical care, and supplies, accounted for \$91.8 billion (13). The estimated cost for foot ulcer care in the US ranges from \$4,595 per ulcer episode to nearly \$28,000 for the 2 years after diagnosis (19, 38). One report estimates 800,000 prevalent ulcer cases in the US, with costs averaging \$5,457 per year per patient or total national annual costs of \$5 billion (39). A study of Medicare claims data found that expenditures for patients with lower extremity ulcers averaged 3 times higher than expenditures for Medicare beneficiaries in general. With 24% of their total costs allocated to ulcer-related expenses, lower extremity ulcer patients cost the Medicare system \$1.5 billion in 1995 (40). According to a large prospective study of diabetic patients with foot ulcers,

about 7% will subsequently require a lower extremity amputation (31). While hospital LOSs for diabetes-related LEA have progressively decreased in the US, the overall direct costs remain high (10, 16). Direct and indirect costs of LEA—which range from \$20,000 to \$40,000 per event—vary by year, payer, level of amputation, LOS, and attendant comorbidities (16). If the lower figure is applied to the 82,000 amputations performed in 2002, estimated total costs of LEA might exceed \$1.6 billion annually. When outpatient costs for ulcer care preceding these amputations is added, the estimated total costs in the US for diabetic foot disease can easily approach or exceed \$6 billion annually.

### **Risk for Ulceration**

Foot ulceration is the most common single precursor to lower extremity amputations among persons with diabetes (28-30). Treatment of infected foot wounds comprises up to one quarter of all diabetic hospital admissions in the US and Britain, making this the most common reason for diabetes-related hospitalization in these countries (41-43). The multifactorial nature of diabetic foot ulceration has been elucidated by numerous observational studies (16, 22, 24, 26, 27, 44-48). Risk factors identified include peripheral neuropathy, vascular disease, limited joint mobility, foot deformities, abnormal foot pressures, minor trauma, a history of ulceration or amputation, and impaired visual acuity (25, 49, 50). These and other putative causative factors are shown in Figure 1.

Peripheral sensory neuropathy in the face of unperceived trauma is the primary factor leading to diabetic foot ulcerations (24, 27, 46, 49). Approximately 45% to 60% of all diabetic ulcerations are purely neuropathic, while up to 45% have neuropathic and ischemic components (24, 51). According to an important prospective multicenter study, sensory neuropathy was the most frequent component in the causal sequence to ulceration in diabetic patients (24).

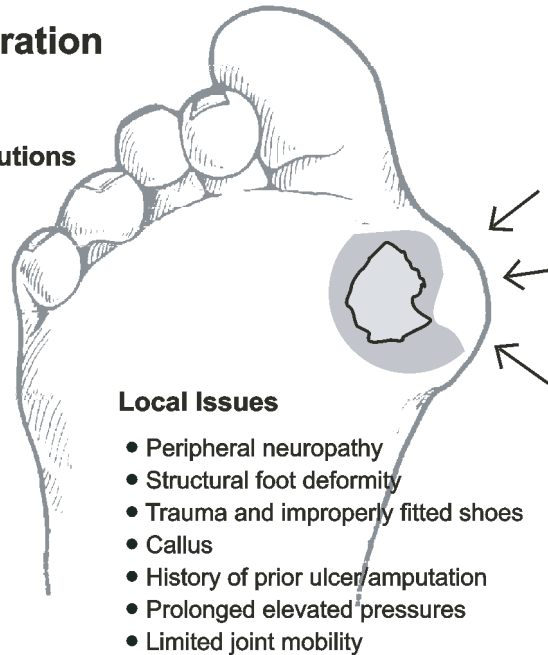
Other forms of neuropathy may also play a role in foot ulceration. Motor neuropathy resulting in anterior crural muscle atrophy or intrinsic muscle wasting can lead to foot deformities such as foot drop, equinus, hammertoe, and prominent plantar metatarsal heads (25, 26, 52-54). Ankle equinus with restricted dorsiflexory range of motion is fairly common in patients with diabetic neuropathy and can be a consequence of anterior crural muscle atrophy (55-60). The decreased ankle motion, which confers higher-than-normal plantar pressures at the forefoot, has been implicated as a contributory cause of ulceration as well as recurrence or recalcitrance of existing ulcers (57, 58, 60, 61).

Autonomic neuropathy often results in dry skin with cracking and fissuring, creating a portal of entry for bacte-

## Risk Factors for Ulceration

### General or Systemic Contributions

- Uncontrolled hyperglycemia
- Duration of diabetes
- Peripheral vascular disease
- Blindness or visual loss
- Chronic renal disease
- Older age



### Local Issues

- Peripheral neuropathy
- Structural foot deformity
- Trauma and improperly fitted shoes
- Callus
- History of prior ulcer/amputation
- Prolonged elevated pressures
- Limited joint mobility

**Figure 1** The risk factors for ulceration may be distinguished by general or systemic considerations versus those localized to the foot and its pathology.

ria (42, 63). Autotomy with attendant sympathetic failure, arteriovenous shunting, and microvascular thermoregulatory dysfunction impairs normal tissue perfusion and microvascular responses to injury. These alterations can subsequently be implicated in the pathogenesis of ulceration (63-67).

Foot deformities resulting from neuropathy, abnormal biomechanics, congenital disorders, or prior surgical intervention may result in high focal foot pressures and increased risk of ulceration (24, 48, 50, 57, 68-71). The effects of motor neuropathy occur relatively early and lead to foot muscle atrophy with consequent development of hammertoes, fat pad displacement, and associated increases in plantar forefoot pressures (53, 72-75). Although most deformities cause high plantar pressures and plantar foot ulcerations, medial and dorsal ulcerations may develop as a result of footwear irritation. Common deformities might include prior partial foot amputations, prominent metatarsal heads, hammertoes, Charcot arthropathy, or hallux valgus (69, 76-79). A large prospective population-based study found that elevated plantar foot pressures are significantly associated with neuropathic ulceration and amputation (80). The study also revealed a trend for increased foot pressures as the number of pedal deformities increased.

Trauma to the foot in the presence of sensory neuropathy is an important component cause of ulceration (24). While trauma may include puncture wounds and blunt injury, a common injury leading to ulceration is moderate repetitive stress associated with walking or day-to-day activity (69, 76, 81). This is often manifested by callus formation under

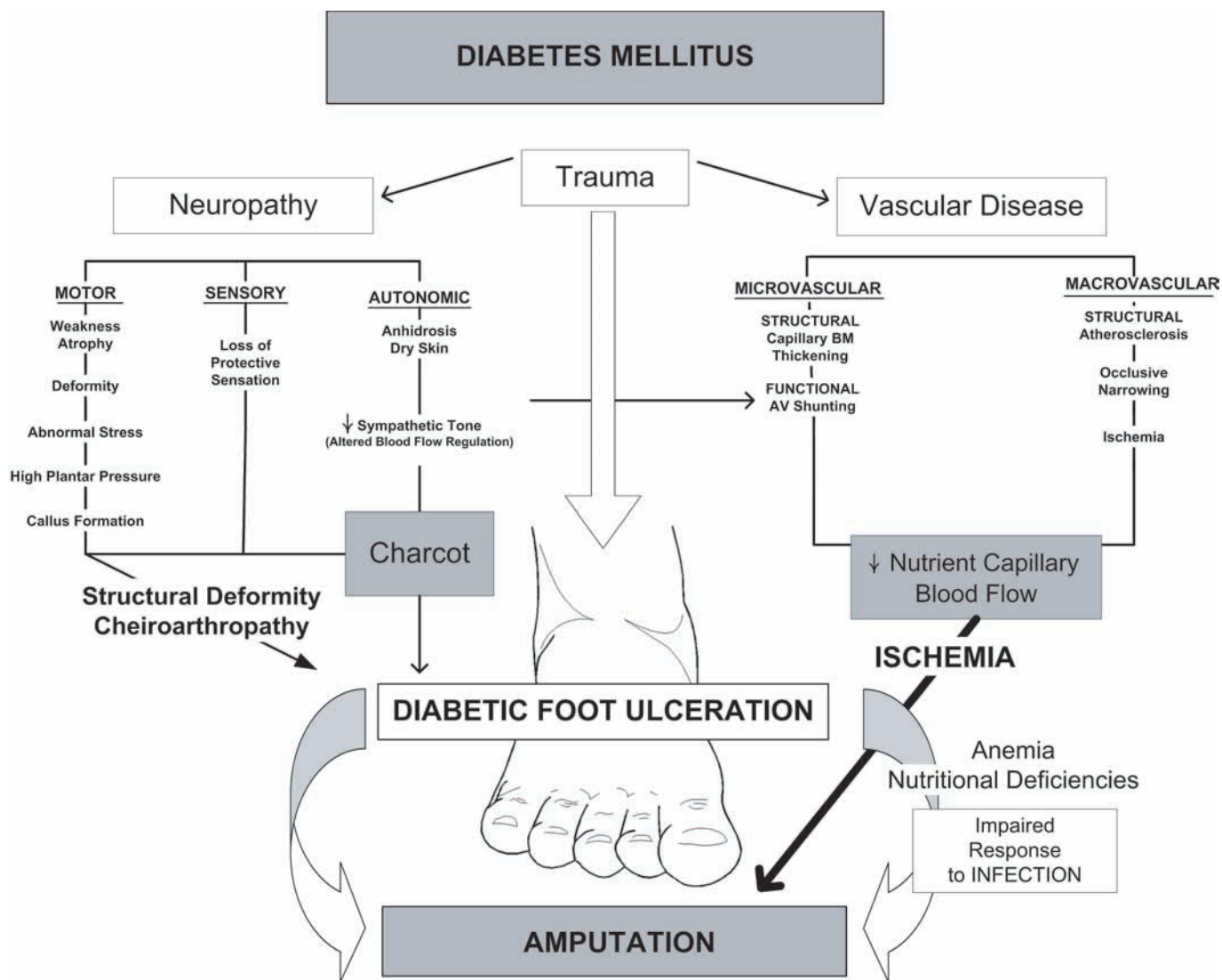
the metatarsal heads (48, 82, 83). A recent report suggests that even with moderate activity, ulceration may be precipitated by a higher degree of variability in activity or periodic "bursts" of activity (84). Shoe-related trauma has also been identified as a frequent precursor to foot ulceration (28, 51, 54, 85, 86).

Peripheral arterial disease (PAD) rarely leads to foot ulcerations directly. However, once ulceration develops, arterial insufficiency will result in prolonged healing, imparting an elevated risk of amputation (28, 87, 88). Additionally, attempts to resolve any infection will be impaired due to lack of oxygenation and difficulty in delivering antibiotics to the infection site. Therefore, early recognition and aggressive treatment of lower extremity ischemia are vital to lower limb salvage (30, 52, 89-91).

Limited joint mobility has also been described as a potential risk factor for ulceration (92-94). Glycosylation of collagen as a result of longstanding diabetes may lead to stiffening of capsular structures and ligaments (cheiroarthropathy) (95). The subsequent reduction in ankle, subtalar, and first metatarsophalangeal (MTP) joint mobility has been shown to result in high focal plantar pressures with increased ulceration risk in patients with neuropathy (92, 96, 97). Several reports also attribute glycosylation and altered arrangement of Achilles tendon collagen to the propensity for diabetic patients to develop ankle equinus (98, 99).

Other factors frequently associated with heightened ulceration risk include nephropathy, poor diabetes control, duration of diabetes, visual loss, and advanced age (48, 69,





**Figure 2** Diabetes mellitus is responsible for a variety of foot pathologies contributing to the complications of ulceration and amputation. Multiple pathologies may be implicated, from vascular disease to neuropathy to mechanical trauma.

93, 100). Soft tissue changes (other than cheiroarthropathy) in the feet of diabetic patients might also contribute to ulceration through the pathway of altered pressure distributions through the sole of the foot. Such alterations include a reported increased thickness of the plantar fascia with associated limitation of hallux dorsiflexion, decreased thickness of plantar soft tissue, accentuated hardness/stiffness of the skin, and a propensity to develop calluses (82, 96, 101-105). While these changes are presumably caused by glycosylation of collagen, their sum effect is to enhance plantar pressures in gait. In the presence of neuropathy, the accentuated plantar pressures can be implicated in the development of ulceration (70, 80, 92, 106).

### Mechanisms of Injury

The multifactorial etiology of diabetic foot ulcers is evidenced by the numerous pathophysiologic pathways that can potentially lead to this disorder (24, 43, 54, 62, 90, 107). Among these are two common mechanisms by which foot deformity and neuropathy may induce skin breakdown in persons with diabetes (69, 108, 109).

The first mechanism of injury refers to prolonged low pressure over a bony prominence (ie, bunion or hammertoe deformity). This generally causes wounds over the medial, lateral, and dorsal aspects of the forefoot and is associated with tight or ill-fitting shoes. Shoe trauma, in concert with loss of protective sensation and concomitant foot deformity, is the leading event precipitating foot ulceration in persons with diabetes (24, 28, 57, 85).

Regions of high pedal pressure are frequently associated with foot deformity (68, 73, 76, 77, 106, 107). When an abnormal focus of pressure is coupled with lack of protective sensation, the result can be development of a callus, blister, and ulcer (110). The other common mechanism of ulceration involves prolonged repetitive moderate stress (108). This normally occurs on the sole of the foot and is related to prominent metatarsal heads, atrophied or anteriorly displaced fat pads, structural deformity of the lower extremity, and prolonged walking. Rigid deformities such as hallux valgus, hallux rigidus, hammertoe, Charcot arthropathy, and limited range of motion of the ankle (equinus), subtalar, and MTP joints have been linked to the development of diabetic foot ulcers (27, 57, 71, 80, 94, 96). Numerous studies support the significant association between high plantar pressures and foot ulceration (26, 70, 80, 92, 106, 111, 112). Other biomechanical perturbations, including partial foot amputations, have the same adverse effects (57, 68, 80, 113).

Figure 2 summarizes the various pathways and contributing factors leading to diabetic foot complications.

### **Risk for Infection**

Infections are common in diabetic patients and are often more severe than infections found in nondiabetic patients. Persons with diabetes have an increased risk for developing an infection of any kind and a several-fold risk for developing osteomyelitis (114). With an incidence of 36.5 per 1,000 persons per year, foot infections are among the most common lower extremity complications in the diabetic population (excluding neuropathy), second only to foot ulcers in frequency (115).

It is well documented that diabetic foot infections are frequently polymicrobial in nature (30, 116-121). Hyperglycemia, impaired immunologic responses, neuropathy, and peripheral arterial disease are the major predisposing factors leading to limb-threatening diabetic foot infections (122-124). Uncontrolled diabetes results in impaired ability of host leukocytes to fight bacterial pathogens, and ischemia also affects the ability to fight infections because delivery of antibiotics to the site of infection is impaired. Consequently, infection can develop, spread rapidly, and produce significant and irreversible tissue damage (125). Even in the presence of adequate arterial perfusion, underlying peripheral sensory neuropathy will often allow the progression of infection through continued walking or delay in recognition (126, 127).

### **Risk for Charcot Joint Disease**

It has been estimated that less than 1% of persons with diabetes will develop Charcot joint disease (128-130). Data on the true incidence of neuroarthropathy in diabetes are limited by the paucity of prospective or population-based studies in the literature. One large population-based prospective study found an incidence of about 8.5 per 1,000 persons with diabetes per year (115); this equates to 0.85% per year and is probably the most reliable figure currently available. Much of the data clinicians rely upon have been extracted from retrospective studies of small, single-center cohorts. The incidence of reported Charcot cases is likely to be underestimated because many cases go undetected, especially in the early stages (131-134).

Primary risk factors for this potentially limb-threatening deformity are the presence of dense peripheral sensory neuropathy, normal circulation, and history of preceding trauma (often minor in nature) (50, 135, 136). Trauma is not limited to injuries such as sprains or contusions. Foot deformities, prior amputations, joint infections, or surgical trauma may result in sufficient stress that can lead to Charcot joint disease (137-140).

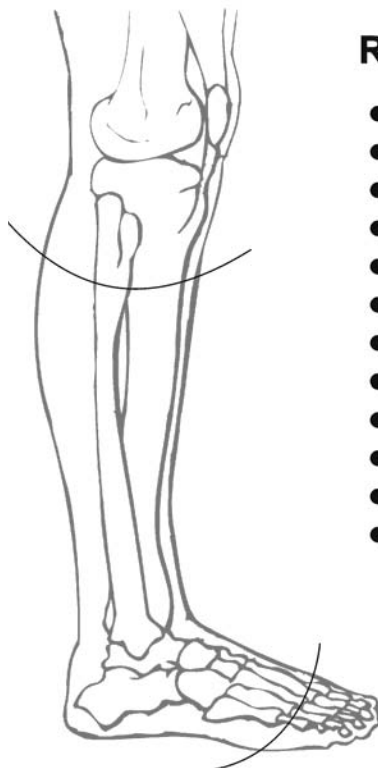
### **Risk for Amputation**

The reported risk of lower extremity amputations in diabetic patients ranges from 2% to 16%, depending on study design and the populations studied (19, 21, 32, 115, 141-144). LEA rates can be 15 to 40 times higher among the diabetic versus nondiabetic populations (8, 16, 34, 35). Although one author suggests that amputation may be a marker not only for disease severity but also for disease management, it is clear that amputation remains a global problem for all persons with diabetes (32, 143). The same risk factors that predispose to ulceration can also generally be considered contributing causes of amputation, albeit with several modifications (Fig 3).

While peripheral arterial disease may not always be an independent risk factor for ulceration when controlling for neuropathy, it can be a significant risk factor for amputation (24, 28, 88, 142, 145, 146). PAD affecting the feet and legs is present in 8% of adult diabetic patients at diagnosis and in 45% after 20 years (147, 148). The incidence of amputation is 4 to 7 times greater for diabetic men and women than for their nondiabetic counterparts. Impairment of arterial perfusion may be an isolated cause for amputation and a predisposing factor for gangrene. Early diagnosis, control of risk factors, and medical management as well as timely revascularization may aid in avoiding limb loss (30, 52, 77, 88, 149).



**Figure 3** The risk factors for amputation are multifactorial and similar to those for ulceration.



## Risk Factors for Amputation

- Neuropathy LOPS
- Peripheral arterial disease (PAD)
- Infection
- History of prior foot ulcer or amputation
- Structural foot deformity
- Trauma
- Charcot foot
- Impaired vision
- Poor glycemic control
- Older age
- Male Sex
- Ethnicity (greatest rates in blacks & Hispanics)

While infection is not often implicated in the pathway leading to ulceration, it is a significant risk factor in the causal pathway to amputation (24, 28). Lack of wound healing, systemic sepsis, or unresolved infection can lead to extensive tissue necrosis and gangrene, requiring amputation to prevent more proximal limb loss. This includes soft tissue infection with severe tissue destruction, deep space abscess, or osteomyelitis. Adequate debridement may require amputation at some level as a means of removing all infected material (77, 123, 150, 151).

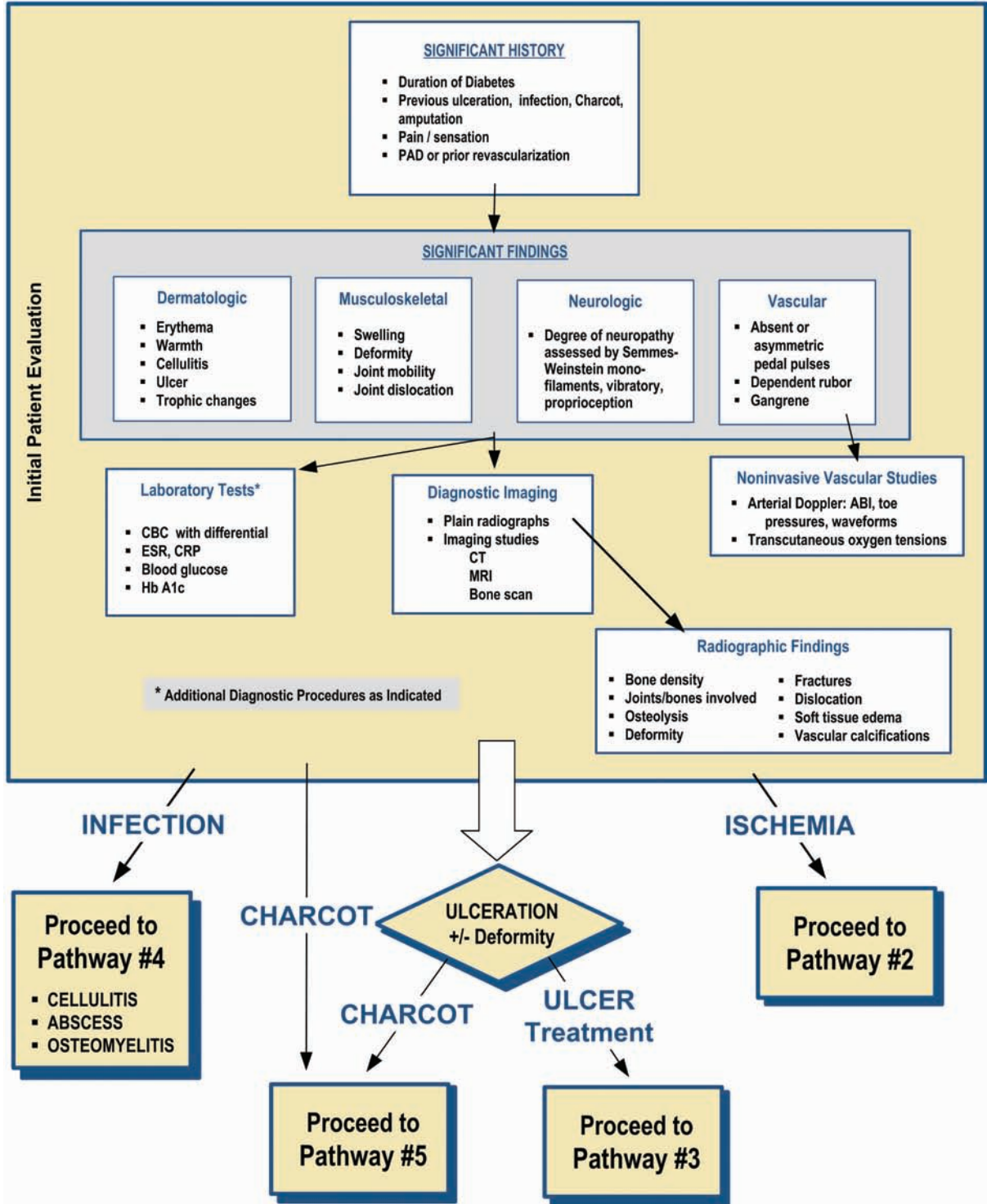
Another frequently described risk factor for amputation is chronic hyperglycemia. Results of the Diabetes Control and Complications Trial (DCCT) and the United Kingdom Prospective Diabetes Study (UKPDS) support the long-held theory that chronic poor control of diabetes is associated with a host of systemic complications (152, 153). The link between degree of glucose control and incidence or progression of numerous diabetic complications has been well established by these and other studies (154, 155). Such complications include peripheral neuropathy, microangiopathy, microcirculatory disturbances, impaired leukocyte phagocytosis, and glycosylation of tissue proteins. Each has adverse effects on the diabetic foot: They can contribute to the etiology of foot ulceration, delay normal wound healing, and subsequently lead to amputation (25, 30, 48, 50, 72). Several studies have reported a significant correlation between elevated glucose and LEA (21, 141,

156-161). Amputation has also been associated with other diabetes-related comorbidities such as nephropathy, retinopathy, and cardiovascular disease (21, 48, 144). Aggressive glucose control, management of associated comorbidities, and appropriate lower extremity care coordinated in a team environment may indeed lower overall risk for amputation (30, 90, 162-166).

The best predictor of amputation is a history of previous amputation. A past history of a lower extremity ulceration or amputation increases the risk for further ulceration, infection, and subsequent amputation (29, 142, 157, 167). It may also be inferred that patients with previous ulceration possess all the risk factors for developing another ulceration, having demonstrated that they already have the component elements in the causal pathway (24, 27, 28, 57). Up to 34% of patients develop another ulcer within 1 year after healing an index wound, and the 5-year rate of developing a new ulcer is 70% (164, 168). The recurrence rate is higher for patients with a previous amputation because of abnormal distribution of plantar pressures and altered osseous architecture. The cumulative risks of neuropathy, deformity, high plantar pressure, poor glucose control, and male gender are all additive factors for pedal ulceration in these diabetic patients (26, 46, 50, 57, 111). Re-amputation can be attributed to disease progression, nonhealing wounds, and additional risk factors for limb loss that develop as a result of the first amputation. Tragically, the 5-year survival rate

**PATHWAY #1**

**DIABETIC FOOT DISORDERS**



**INFECTION**

**Proceed to Pathway #4**  

- CELLULITIS
- ABSCESS
- OSTEOMYELITIS

**CHARCOT**

ULCERATION  
+/- Deformity

**CHARCOT**      **ULCER Treatment**

Proceed to Pathway #5

Proceed to Pathway #3

**ISCHEMIA**

Proceed to Pathway #2

after a diabetes-related LEA has been reported to be as low as 28% to 31% (169, 170). Persons with renal failure or more proximal levels of amputation have a poor prognosis and higher mortality rate. Those who undergo a diabetes-related amputation have a 40% to 50 % chance of undergoing a contralateral amputation within 2 years (36, 171, 172).

**ASSESSMENT OF THE DIABETIC FOOT (Pathway 1)**

The pedal manifestations of diabetes are well documented and potentially limb-threatening when left untreated. Recognition of risk factors and treatment of diabetic foot disorders require the skill of a specialized practitioner to diagnose, manage, treat, and counsel the patient. Integration of knowledge and experience through a multidisciplinary team approach promotes more effective treatment, thereby improving outcomes and limiting the risk of lower extremity amputation (30, 173).

The evaluation of the diabetic foot involves careful assimilation of the patient’s history and physical findings with the results of necessary diagnostic procedures

(Pathway 1). Screening tools may be valuable in evaluating the patient and determining risk level (Appendix 1). Early detection of foot pathology, especially in high-risk patients, can lead to earlier intervention and thereby reduce the potential for hospitalization and amputation (100). This is also facilitated by an understanding of the underlying pathophysiology of diabetic foot disorders and associated risk factors. Identification of abnormal historical and/or physical findings can therefore improve the prognosis for a favorable outcome through appropriate—and early—referral (91, 174).

**History**

A thorough medical and foot history must be obtained from the patient. The history should address several specific diabetic foot issues (Table 2).

**Physical Examination**

All patients with diabetes require a pedal inspection whenever they present to any health care practitioner, and

**Table 2 Medical History**

Global History	Foot Specific History	
<ul style="list-style-type: none"> <li>● Diabetes - duration</li> <li>● Glycemic management/control</li> <li>● Cardiovascular, renal and ophthalmic evaluations</li> <li>● Other comorbidities</li> <li>● Treating physicians</li> <li>● Nutritional status</li> <li>● Social habits: alcohol, tobacco, drugs</li> <li>● Current medications</li> <li>● Allergies</li> <li>● Previous hospitalizations/surgery</li> </ul>	General	Wound / Ulcer History
	<ul style="list-style-type: none"> <li>● Daily activities, including work</li> <li>● Footwear</li> <li>● Chemical exposures</li> <li>● Callus formation</li> <li>● Foot deformities</li> <li>● Previous foot infections, surgery</li> <li>● Neuropathic symptoms</li> <li>● Claudication or rest pain</li> </ul>	<ul style="list-style-type: none"> <li>● Location</li> <li>● Duration</li> <li>● Inciting event or trauma</li> <li>● Recurrence</li> <li>● Infection</li> <li>● Hospitalization</li> <li>● Wound care</li> <li>● Off-loading techniques</li> <li>● Wound response</li> <li>● Patient compliance</li> <li>● Interference with wound care (Family or social problems for patient)</li> <li>● Previous foot trauma or surgery</li> <li>● Presence of edema - unilateral vs bilateral</li> <li>● Charcot foot - previous or active</li> <li>● Charcot treatment</li> </ul>

they should receive a thorough lower extremity examination at least once annually (175). Patients with complaints relating to the diabetic foot require more frequent detailed evaluations. The examination should be performed systematically so that important aspects are not overlooked (62). It begins with a gross evaluation of the patient and extremities. Any obvious problem can then receive closer scrutiny.

Key components of the foot examination are presented in Table 3. Although not specifically mentioned in this section, it is assumed that a general medical assessment (including vital sign measurements) will be obtained.

### Diagnostic Procedures

Diagnostic procedures may be indicated in the assessment and care of the diabetic foot. Consideration should be given to the following tests in concert with those suggested by members of the consulting team. It should be noted that many of the following tests lack the ability to impart a definitive diagnosis, necessitating clinical correlation.

### Laboratory Tests

Clinical laboratory tests that may be needed in appropriate clinical situations include fasting or random blood glucose, glycohemoglobin (HbA1c), complete blood count (CBC) with or without differential, erythrocyte sedimentation rate (ESR), serum chemistries, C-reactive protein, alkaline phosphatase, wound and blood cultures, and urinalysis. Caution must be exercised in the interpretation of laboratory tests in these patients, because several reports have documented the absence of leukocytosis in the presence of severe foot infections (117, 122, 151, 176-178). A common sign of persistent infection is recalcitrant hyperglycemia despite usual antihyperglycemic regimens (150).

### Imaging Studies

The diabetic foot may be predisposed to both common and unusual infectious or noninfectious processes, partially because of the complex nature of diabetes and its associated vascular and neuropathic complications. As a result, imaging presentations will vary due to lack of specificity in complex clinical circumstances (179-181). Such variability creates a challenge in the interpretation of imaging studies. Therefore, imaging studies should only be ordered to establish or confirm a suspected diagnosis and/or direct patient management. Distinguishing osteomyelitis from aseptic neuropathic arthropathy is not easy, and all imaging studies (Fig 4) must be interpreted in conjunction with the clinical findings (123, 151).

Plain radiographs should be the initial imaging study in diabetic patients with signs and symptoms of a diabetic foot

disorder (180, 182). Radiographs can detect osteomyelitis, osteolysis, fractures, dislocations seen in neuropathic arthropathy, medial arterial calcification, soft tissue gas, and foreign bodies as well as structural foot deformities, presence of arthritis, and biomechanical alterations (183). Acute osteomyelitis might not demonstrate osseous changes for up to 14 days. Serial radiographs should be obtained in the face of an initial negative radiographic image and a high clinical suspicion of osseous disease (117, 123).

Technetium-99 methylene diphosphonate (Tc-99 MDP) bone scans are often used in diabetic foot infection to determine the presence of osteomyelitis. Although highly sensitive, this modality lacks specificity in the neuropathic foot (184, 185). Osteomyelitis, fractures, arthritis, and neuropathic arthropathy will all demonstrate increased radiotracer uptake. However, a negative bone scan is strong evidence against the presence of infection. To improve the specificity of nuclear imaging, white blood cells can be labeled with Tc-99 hexamethylpropyleneamineoxime (Tc-99 HMPAO), indium-111 oxime, or gallium-67 citrate (179, 186-189).

Indium-111 selectively labels polymorphonuclear leukocytes and is more specific for acute infections than Tc-99 MDP scanning. Chronic infections and inflammation are not well imaged with indium-111, because chronic inflammatory cells (ie, lymphocytes) predominate and are not well labeled with indium. Combining Tc-99 MDP and indium-111 increases the specificity of diagnosing osteomyelitis (190). This combined technique is useful, because the Tc-99 MDP scan localizes the anatomic site of inflammation and the indium-111 labels the infected bone (180, 191). The indium-111 scan is not typically positive in aseptic neuropathic arthropathy, although false-positive indium scans can occur (192-194). A 100% sensitivity and 89% specificity have been reported with the combined technique in evaluating diabetic infections (190, 191, 195).

In Tc-99 HMPAO scanning, white blood cells are labeled in a similar manner as in indium scanning. However, with Tc-99 HMPAO scans, imaging occurs 4 hours following administration versus 24 hours postadministration with indium scanning. Tc-99 HMPAO uses a smaller radiation dose, is less expensive, and offers improved resolution compared with indium scanning. The sensitivity and specificity of both techniques are comparable (186, 196). Tc-99 HMPAO scans cannot be combined with Tc-99 MDP scans because of similar labeling characteristics.

Tc-99 sulfur colloid is useful in distinguishing osteomyelitis from neuropathic arthropathy (183). This tracer is picked up by the bone marrow and any hemopoetically-active marrow will be positive. Infected bone replaces normal bone marrow, so it shows up as a relative



Table 3

## Lower Extremity Diabetic Foot Exam

### Vascular Examination

- Palpation of pulses
  - Common femoral, popliteal
  - Dorsalis pedis, posterior tibial
- Handheld Doppler examination
- Skin / limb color changes
  - Cyanosis, erythema
  - Elevation pallor, dependent rubor
- Presence of edema
- Temperature gradient
  - (ipsilateral and contralateral extremity)
- Dermal thermometry
- Integumentary changes
  - Skin atrophy - thin, smooth, parchment-like skin
  - Abnormal wrinkling
  - Absence of hair growth
  - Onychodystrophy
- Previous hospitalizations/surgery

### Neurologic Examination

- Vibration perception
  - Tuning fork 128 cps
  - Measurement of vibration perception threshold (biothesiometer)
- Light pressure:
  - Semmes-Weinstein 10 gram monofilament
- Light touch: cotton wool
- Two point discrimination
- Pain: pinprick (sterile needle)
- Temperature perception: hot and cold
- Deep tendon reflexes: patella, Achilles
- Clonus testing
- Babinski test
- Romberg test

### Footwear Examination

- Type of shoe (athletic, oxford, comfort, etc.)
- Fit
- Depth of toe box
- Shoewear, patterns of wear
- Lining wear
- Foreign bodies
- Insoles, orthoses

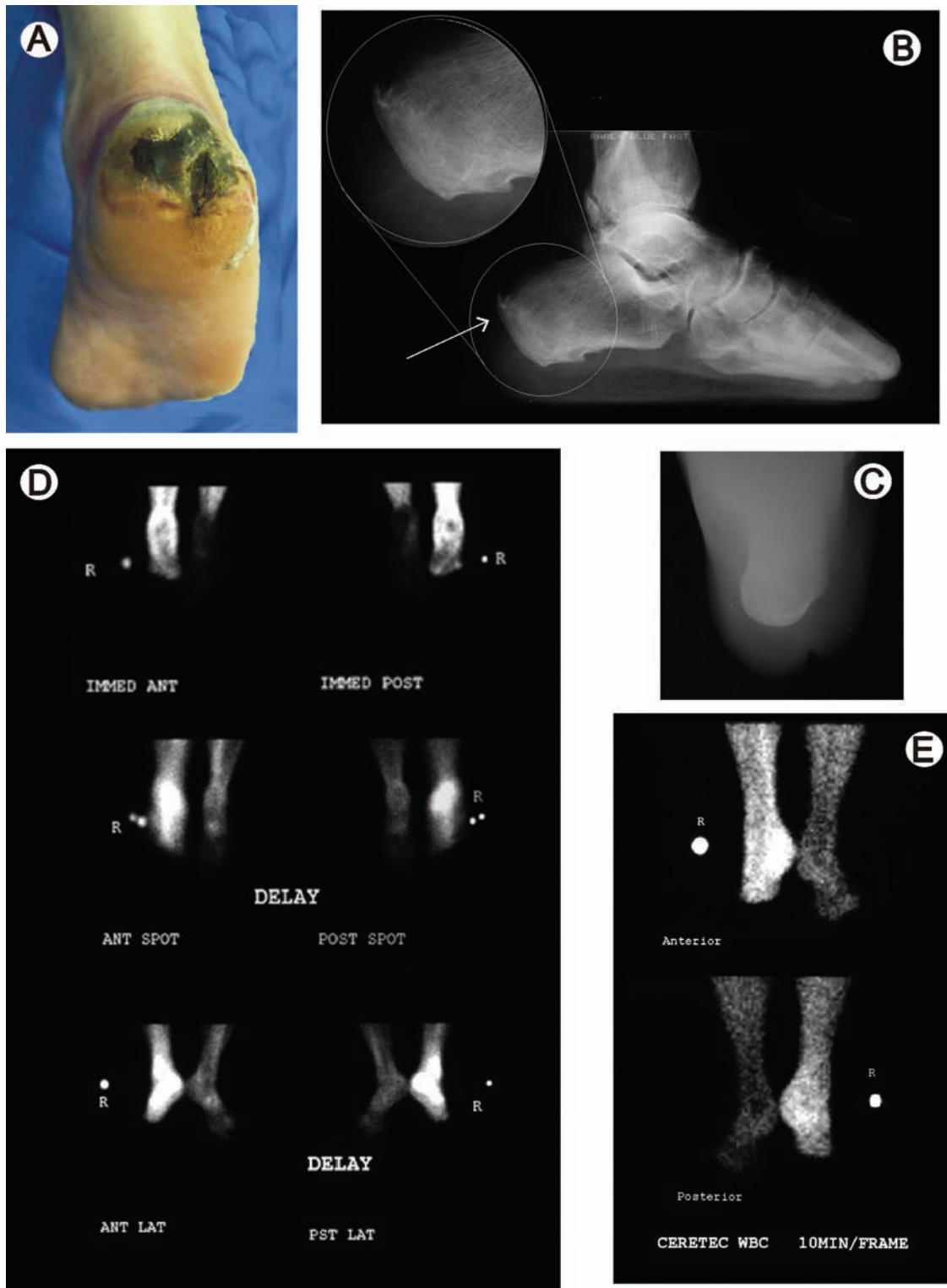
### Dermatologic Examination

- Skin appearance
  - Color, texture, turgor, quality
  - Dry skin
- Calluses
  - Discoloration / subcallus hemorrhage
- Fissures (especially posterior heels)
- Nail appearance
  - Onychomycosis, dystrophic, gryphotic
  - Atrophy or hypertrophy
  - Paronychia
- Hair growth
- Ulceration, gangrene, infection
  - Note location, size, depth, infection status, etc.
- Interdigital lesions
- Tinea pedis
- Markers of diabetes
  - Shin spots - diabetic dermopathy
  - Necrobiosis lipoidica diabetorum
  - Bullosum diabeticorum
  - Granuloma annulare
  - Acanthosis nigricans

### Musculoskeletal Examination

- Biomechanical abnormalities
- Structural deformities
  - Hammertoe, bunion, tailor's bunion
  - Hallux limitus/rigidus
  - Flat or high-arched feet
  - Charcot deformities
  - Postsurgical deformities (amputations)
- Prior amputation
- Limited joint mobility
- Tendo-Achilles contractures / equinus
- Gait evaluation
- Muscle group strength testing
  - passive and active, non-weightbearing and weightbearing
  - Foot drop
  - Atrophy - intrinsic muscle atrophy
- Plantar pressure assessment
  - Computerized devices
  - Harris ink mat, pressure sensitive foot mat





**Figure 4** Diagnostic imaging plays an important role in the evaluation of diabetic foot infections. (A) This patient presented with a deep foul-smelling necrotic ulcer of the heel that had been present for more than 1 month. (B) In the past, a technetium bone scan typically would be performed, but the imaging is nonspecific and many false positive results interpretative as osteomyelitis were seen. (C) White blood cell tagged imaging with indium or technetium is a more reliable technique for detecting the presence of infection.

“cold spot.” This technique is best combined with indium scanning, and osteomyelitis would appear as a “hot” indium scan and a “cold” sulfur colloid scan (183, 193).

Computed tomography (CT) scans may be indicated in the assessment of suspected bone and joint pathology not evident on plain radiographs (180, 197). CT offers high anatomic detail and resolution of bone with osseous fragmentation and joint subluxation (198). Subluxation of the transverse tarsal or tarsometatarsal joints can be seen prior to being visualized on radiographs.

Magnetic resonance imaging (MRI) is usually preferred over CT for the investigation of osteomyelitis, because of its enhanced resolution and ability to visualize the extent of any infectious process (183, 199). MRI is often used in evaluating soft tissue and bone pathology. This scan may be indicated to aid in the diagnosis of osteomyelitis, deep abscess, septic joint, and tendon rupture. It is a readily available modality that has a very high sensitivity for bone infection and can also be used for surgical planning (123, 200-203). Despite its high cost, MRI has gained wide acceptance in the management of diabetic foot infections. When neuropathic arthropathy is present, the T1 and T2 bone images are hypointense (ie, decreased signal) and the soft tissues show edema. Increased signal on T-2 bone images is seen in osteomyelitis; however, tumors and avascular necrosis can also be hyperintense on T-2 (204). MRI is an excellent modality for assessing the presence of a soft tissue abscess, especially if gadolinium administration is utilized (205, 206). Postcontrast fat suppression images should be obtained, if available (207).

Positive emission tomography (PET) scanning is a promising new technique for distinguishing osteomyelitis from neuropathic arthropathy, but it currently is not widely available (109, 208, 209). A recent meta-analysis comparing the diagnostic accuracy of PET scanning with bone and leukocyte scanning found that PET scans were the most accurate modality for diagnosing osteomyelitis, providing a sensitivity of 96% and specificity of 91% (190). When PET scanning was unavailable, an indium-labeled leukocyte scan was found to be an acceptable alternative, offering a sensitivity of 84% and specificity of 80% in the peripheral skeleton (190).

The use of ultrasound for detecting chronic osteomyelitis has been shown to be superior to plain radiographs, providing sensitivity comparable to Tc-99 MDP bone scanning (210). Although ultrasound is a widely available, cost-effective imaging modality, MRI is more accurate and is the imaging study of choice if radiographs are normal and clinical suspicion is high for bone or soft tissue infection (211).

## Vascular Evaluation

The lower extremity must be assessed for vascular and neuropathic risk factors. Although positive findings in the neurologic examination rarely require further evaluation, positive findings of vascular insufficiency may require further consultation. The indications for vascular consultation include an ankle brachial index of less than 0.7, toe blood pressures less than 40 mmHg, or transcutaneous oxygen tension (TcPO<sub>2</sub>) levels less than 30 mmHg, since these measures of arterial perfusion are associated with impaired wound healing (27, 47, 87, 90, 212, 213).

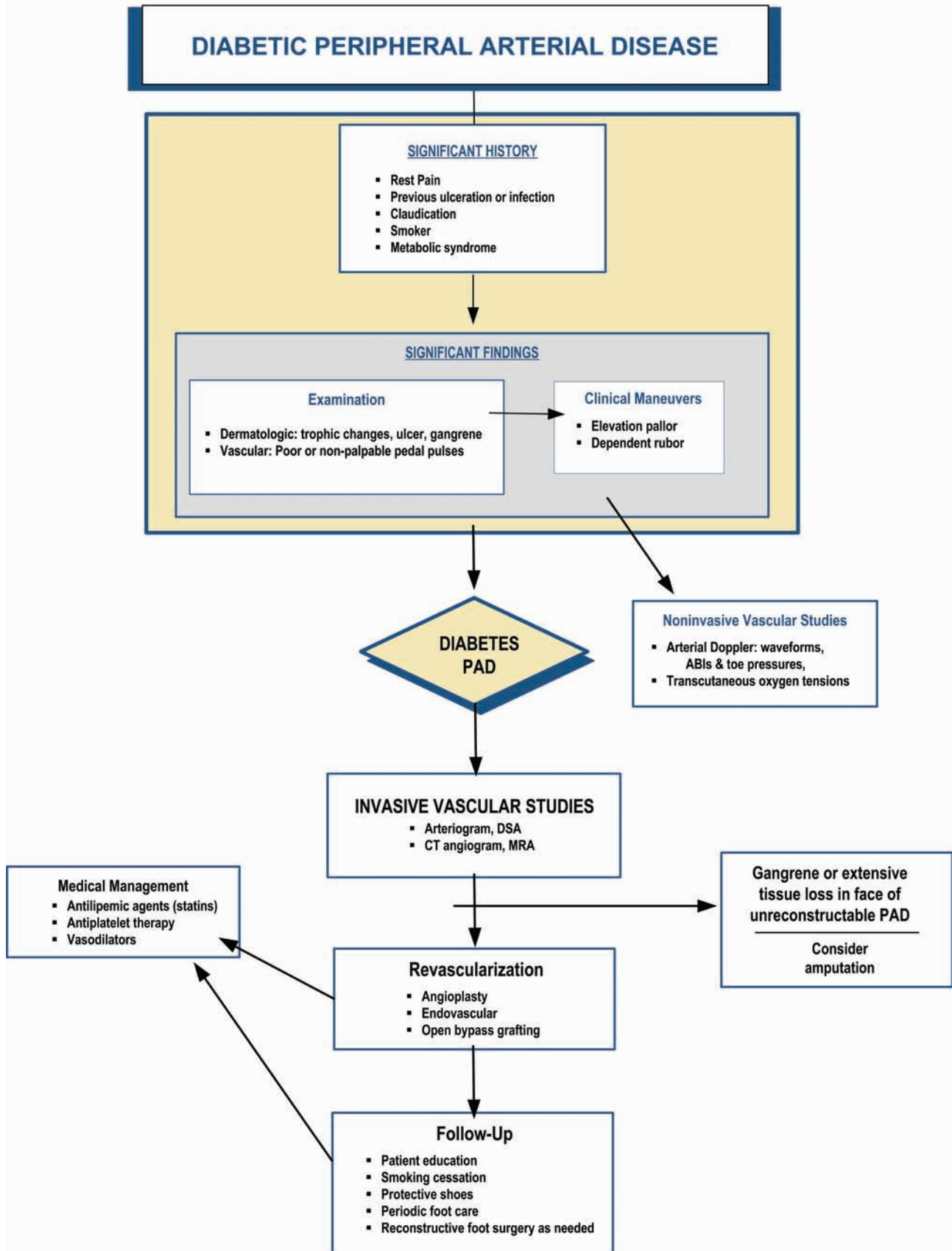
If the history and physical examination suggest ischemia (ie, absent pedal pulses) or if a nonhealing ulcer is present, further evaluation in the form of noninvasive testing is warranted (Pathway 2).

Noninvasive arterial studies should be performed to determine lower extremity perfusion. Such studies may include Doppler segmental arterial pressures and waveform analysis, ankle-brachial indices (ABI), toe blood pressures, and TcPO<sub>2</sub> (89, 214, 215). Ankle-brachial indices may be misleading, because ankle pressures can be falsely elevated due to medial arterial calcinosis and noncompressibility of affected arteries (52, 216, 217). A growing body evidence suggests that toe blood pressures in diabetic patients may have a role in predicting foot ulceration risk as well as predicting successful wound healing (213, 218, 219). TcPO<sub>2</sub> measurements have received similar support in the literature (47, 87, 212). Although not consistently predictive of wound healing outcomes, these physiologic measures of tissue oxygenation are highly predictive of wound healing failure at levels below 25 mmHg (87, 212, 220). Both tests can be performed distally on the foot regardless of arterial calcification in the major pedal arteries, and they are both favorable at pressures in the range of 40 mmHg (90, 212, 213).

Laser Doppler velocimetry and measurement of skin perfusion pressure (SPP) have primarily been used in research settings, but can accurately assess blood flow and oxygen tension in the superficial arterioles and capillaries of the skin (220-225). Several recent reports indicate that laser Doppler measurement of SPP can be highly predictive of critical limb ischemia and wound healing failure at levels less than 30 mmHg (223, 224).

Vascular consultation should be considered in the presence of abnormal noninvasive arterial studies or a nonhealing ulceration (30, 54, 173, 215, 226). Arteriography with clearly visualized distal runoff allows appropriate assessment for potential revascularization (227-229). Magnetic resonance angiography (230) or CT angiogram are alternatives for evaluation of distal arterial perfusion (229, 231).

**PATHWAY #2**



## Neurologic Evaluation

Peripheral sensory neuropathy is the major risk factor for diabetic foot ulceration (24, 26, 27, 46, 50). The patient history and physical examination utilizing the 5.07 Semmes-Weinstein monofilament (10-g) wire are sufficient to identify individuals at risk for ulceration (26, 232-235).

Vibration perception threshold assessment with the biothesiometer is also useful in identifying patients at high risk for ulceration (44, 57, 236). More sophisticated studies such as nerve conduction studies are rarely necessary to diagnose peripheral sensory neuropathy. Patients with neuropathic ulcerations usually have such profound sensory neuropathy that these studies add little to their clinical management (49).

## Plantar Foot Pressure Assessment

High plantar foot pressure is a significant risk factor for ulceration (26, 45, 59, 70, 76, 80, 237). Measurement of high plantar foot pressure is possible utilizing a variety of modalities. Several computerized systems can provide quantitative measurement of plantar foot pressure (76, 81, 238-241). While these measurements may be important in identifying areas of the foot at risk for ulceration and possibly in evaluating orthotic adjustments (57, 59), they are primarily used in diabetic foot research. The Harris mat, while not as sophisticated, can provide a qualitative measurement of plantar foot pressures and can identify potentially vulnerable areas for ulceration.(242). A newer noncomputerized device (PressureStat®, FootLogic, New York City, NY), which is similar to the Harris mat and uses pressure-sensitive contact sheets that provide a semi-quantitative estimation of pressure distribution under the foot, has been suggested as an inexpensive screening tool for identifying areas at high risk for ulceration (76, 243).

## Risk Stratification

Following a thorough diabetic foot examination, the patient may be classified according to a cumulative risk cat-

egory. This enables the physician to design a treatment plan and determine whether the patient is at risk for ulceration or amputation. Several risk stratification schemes have been proposed, assigning different weights to important risk factors for ulceration including peripheral neuropathy, arterial insufficiency, deformity, high plantar pressures, and prior history of ulceration or amputation (48, 57, 62, 90, 244-246). Although no one system has been universally adopted to predict complications, Table 4 presents a simplified risk stratification that has been endorsed by an international consensus group and others (90, 247).

## THE HEALTHY DIABETIC FOOT: PREVENTION STRATEGIES

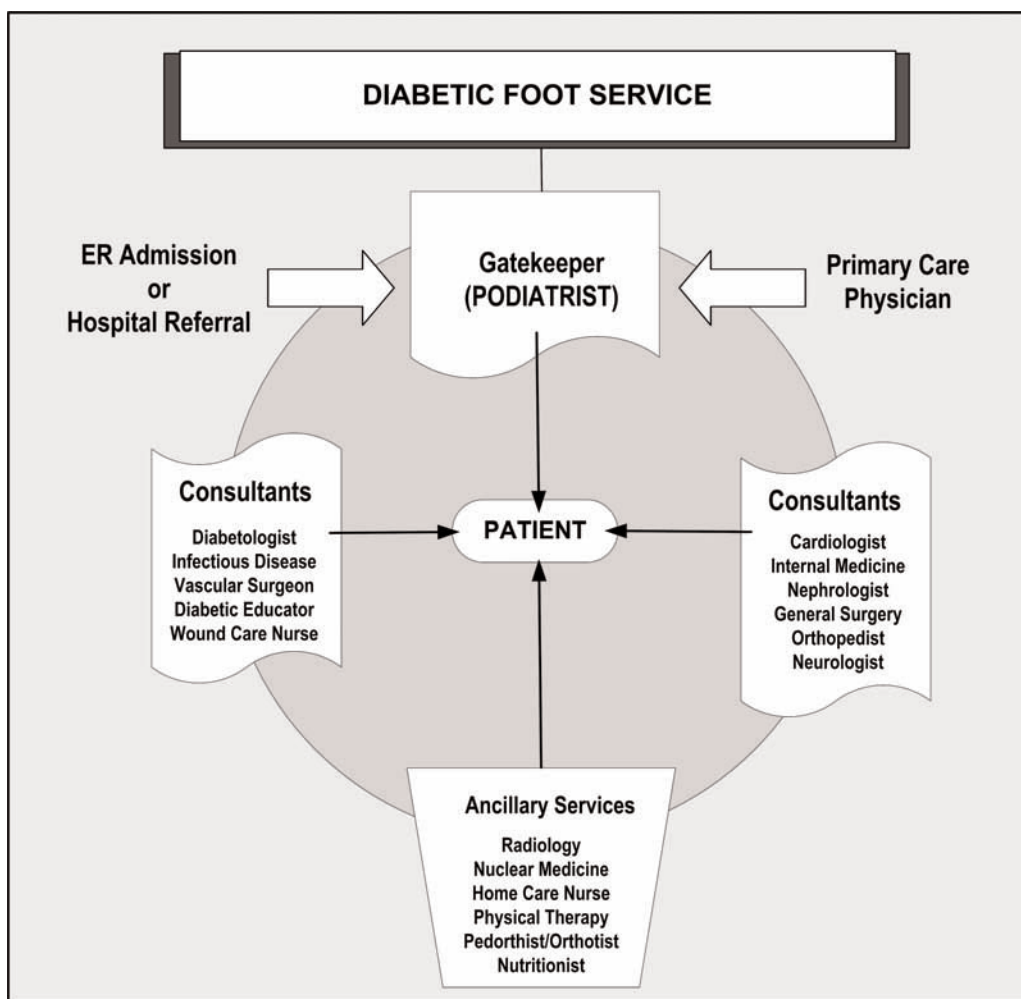
A healthy, intact diabetic foot is best maintained by a consistent and recurrent preventive treatment strategy (2, 30, 43, 48, 90, 163, 246, 248). This is best accomplished through a multidisciplinary approach involving a team of specialists and personnel who provide a coordinated process of care (Fig 5). Team members may include a podiatrist, internist, ophthalmologist, endocrinologist, infectious disease specialist, cardiologist, nephrologist, vascular surgeon, orthopedic surgeon, nurse (educator, wound care, and home care), and pedorthist/orthotist.

Patient and family education assumes a primary role in prevention. Such education encompasses instruction in glucose assessment, insulin administration, diet, daily foot inspection and care, proper footwear, and the necessity for prompt treatment of new lesions (163, 174, 249-251). Regularly scheduled podiatric visits, including debridement of calluses and toenails, are opportunities for frequent foot examination and patient education (163, 252). Such visits can provide early warning of impending problems and subsequent modification of activity and care (30, 253).

Diabetes is a lifelong problem, and the incidence of diabetic foot complications increases with age and dura-

**Table 4 Risk Categorization System**

Category	Risk Profile	Evaluation Frequency
0	Normal	Annual
1	Peripheral neuropathy (LOPS)	Semi-annual
2	Neuropathy, deformity and/or PAD	Quarterly
3	Previous ulcer or amputation	Monthly to quarterly



**Figure 5** A diabetic foot service is composed of a variety of specialists generally needed to evaluate and treat the pathology seen in the patient with diabetes. Effective management must include appropriate consultation for treatment of known comorbidities.

tion of the disease. A recent Markov analysis of the cost effectiveness of foot care according to published guidelines found that such preventive care can improve survival, reduce ulceration and amputation rates, is cost-effective, and can even save on long-term costs when compared with standard care (254).

Risk stratification based on the presence of predisposing causal risk factors, including prior history of ulceration, also serves as a guide to the frequency of foot care visits. By identifying high-risk patient and tailoring a total foot care prevention program accordingly, the incidences of ulceration and lower extremity amputations can be reduced (253, 255-258).

Therapeutic shoes with pressure-relieving insoles and high toe boxes are important adjunctive treatments that can reduce the occurrence of ulceration and resultant amputation in high-risk patients (51, 86, 259-262). While most

studies support the efficacy of protective footwear in this regard, two reports suggest that shoes in the absence of a comprehensive prevention program might not be sufficient to prevent new lesions (263, 264). Nevertheless, patients with foot deformities that cannot be accommodated by standard therapeutic footwear should have custom shoes that provide appropriate fit, depth, and a rocker insole (260, 265-269). If structural deformities cannot be accommodated by therapeutic footwear, prophylactic surgical correction should be considered, but patients must be carefully selected (173, 255, 270-273).

Diabetic patients at risk for foot lesions must be educated about risk factors and the importance of foot care (48, 274-276), including the need for self-inspection and surveillance, monitoring foot temperatures, appropriate daily foot hygiene, use of proper footwear, good diabetes control, and prompt recognition and professional treatment of newly dis-



covered lesions. Home temperature assessment of the foot has been shown to reduce the incidence of foot ulcers 10-fold compared with standard preventive care (277). Patients with visual or physical impairments that preclude their own care should engage the assistance of family or friends to aid in this regard (275). When combined with a comprehensive approach to preventive foot care, patient education can reduce the frequency and morbidity of limb threatening diabetic foot lesions (274, 278, 279).

Provider education is equally important in prevention, since not all clinicians are cognizant of important signs and risk factors for pedal complications (163, 174, 276). Furthermore, provider education is effective in reinforcing proper diabetes management and foot care practices, resulting in reductions in ulceration and adverse lower extremity outcomes (48, 276, 280-282).

### **PATHOLOGIC ENTITIES OF THE DIABETIC FOOT (Foot Ulcer, Infection, Charcot Foot)**

Effective management of diabetic foot disorders requires knowledge of the potential pathologies, the associated classification systems, and the principle tenets of intervention. Ulceration, infection, and Charcot arthropathy are the most significant of these pathologies and classification systems have been developed for each entity. While the conditions may be seen either as an isolated event or coexisting in the same extremity, each entity is examined independently in this clinical practice guideline.

#### **DIABETIC FOOT ULCERS (Pathway 3)**

##### **Evaluation of Ulcers**

The initial evaluation of the diabetic foot ulcer must be comprehensive and systematic to ascertain the parameters that might have led to its onset as well as determine the presence of factors that can impair wound healing (25, 52, 54). Critical in this regard are assessments for vascular perfusion (ischemia), infection/osteomyelitis, and neuropathy. As previously discussed, a thorough vascular evaluation must be performed; this includes palpation of pulses, clinical evaluation of capillary filling time, venous filling time, pallor on elevation, and dependent rubor (283). If pulses are not palpable or if clinical findings suggest ischemia, noninvasive arterial evaluation (eg, segmental Doppler pressures with waveforms, ankle brachial indices, toe pressures, TcPO<sub>2</sub> measurements) and vascular surgical consultation are warranted. When required, these physiologic and anatomic data can be supplemented with the use of magnetic resonance angiography (230) or CT angiography (CTA) and subsequent use of arteriography with digital subtraction angiography (DSA) as necessary (77, 89, 284).

Description of the ulcer characteristics on presentation is essential for the mapping of the ulcer's progress during treatment (30, 43). While some characteristics are more important than others, they all have prognostic value during management. The presumed etiology of the ulcer (ie, chemical vs mechanical) and character of the lesion (neuropathic, ischemic, or neuroischemic) should be determined (90). The evaluation should also describe the size and depth of the ulcer as well as the margins, base, and geographic location on the extremity or foot. All but the most superficial ulcers should be examined with a blunt, sterile probe. The description should note whether the sterile probe detects sinus tract formation, undermining of the ulcer margins, or dissection of the ulcer into tendon sheaths, bone, or joints. A positive probe to bone (PTB) finding is highly predictive of osteomyelitis, although the frequency of false-negative tests reduces its sensitivity (119, 123, 285). Perhaps most importantly, the positive predictive value for PTB falls off significantly when the prevalence of osteomyelitis decreases (286).

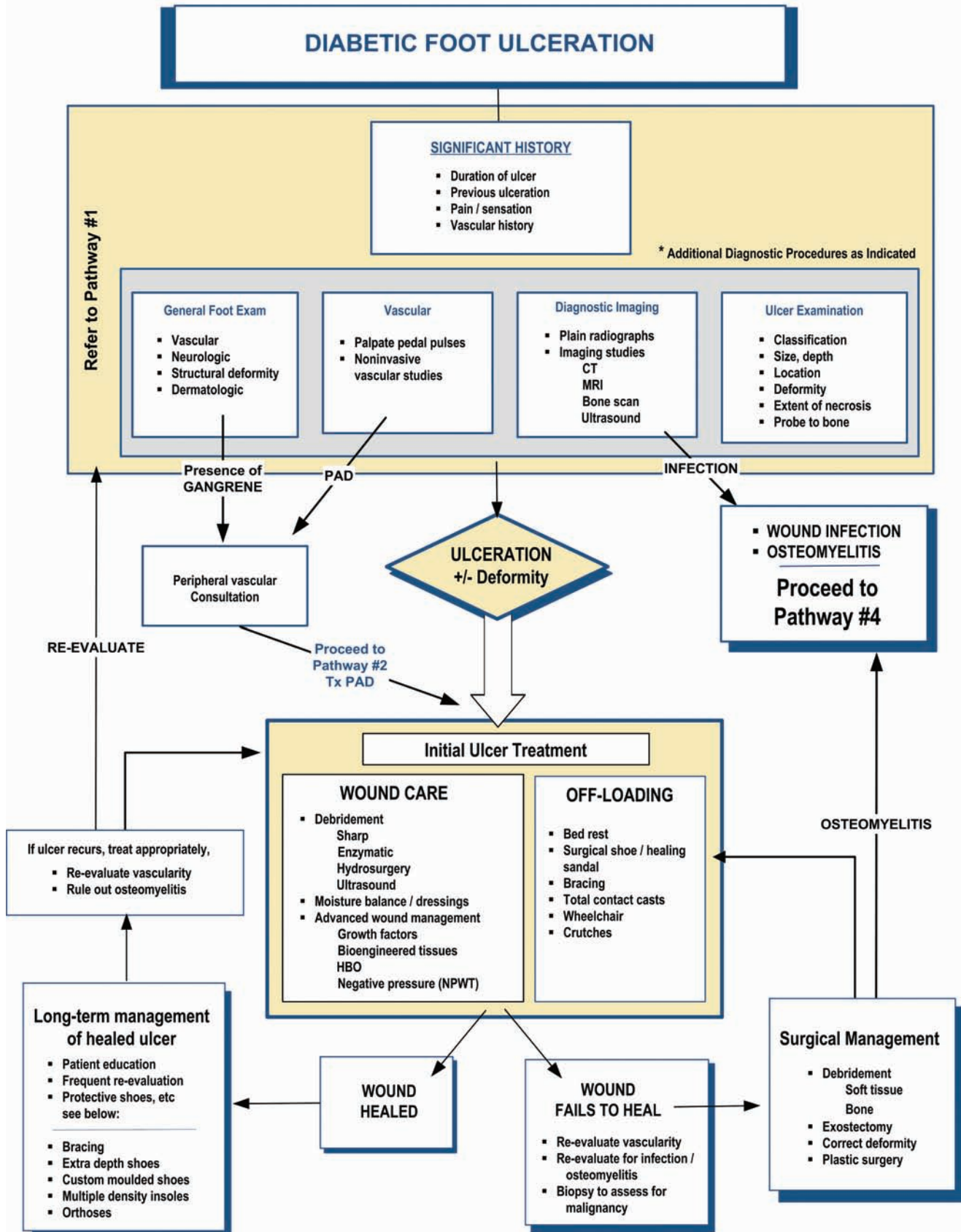
The existence and character of odor or exudate should be noted. Cultures may be necessary when signs of inflammation are present. Generally, clinically uninfected ulcers without inflammation should not be cultured (30, 123). Current recommendations for culture and sensitivity include thorough surgical preparation of the wound site with curettage of the wound base for specimen or with aspiration of abscess material (30, 287).

##### **Classification of Ulcers**

Appropriate classification of the foot wound is based on a thorough assessment. Classification should facilitate treatment and be generally predictive of expected outcomes. Several systems of ulcer classification are currently in use in the US and abroad to describe these lesions and communicate severity (62, 90, 288-292). Perhaps the easiest system is to classify lesions as neuropathic, ischemic, or neuroischemic, with descriptors of wound size, depth, and infection (90). Regardless of which system is used, the clinician must be able to easily categorize the wound and, once classified, the ensuing treatment should be directed by the underlying severity of pathology.

Although no single system has been universally adopted, the classification system most often used was described and popularized by Wagner (292). In the Wagner system (Table 5), foot lesions are divided into six grades based on the depth of the wound and extent of tissue necrosis. Since these grades fail to consider the important roles of infection, ischemia, and other comorbid factors, subsequent authors have modified the classification system by including

# PATHWAY #3



**Table 5**      **Wagner Classification System**

<b>Grade</b>	<b>Lesion</b>
<b>0</b>	<b>No open lesions: may have deformity or cellulitis</b>
<b>1</b>	<b>Superficial ulcer</b>
<b>2</b>	<b>Deep ulcer to tendon or joint capsule</b>
<b>3</b>	<b>Deep ulcer with abscess, osteomyelitis, or joint sepsis</b>
<b>4</b>	<b>Local gangrene - forefoot or heel</b>
<b>5</b>	<b>Gangrene of entire foot</b>

descriptors for these considerations (62, 290, 291). For example, the University of Texas San Antonio (UTSA) system (Table 6) associates lesion depth with both ischemia and infection (290). This system has been validated and is generally predictive of outcome, since increasing grade and stage of wounds are less likely to heal without revascularization or amputation (290, 293). The UTSA system is now widely used in many clinical trials and diabetic foot centers. Another hybrid system, the PEDIS system, evaluates five basic characteristics: perfusion, extent/size, depth/tissue loss, infection and sensation (294) (Table 7). While this system has yet to be validated, it provides the benefit of having been developed by a consensus body.

Imaging studies play an important role in the assessment and evaluation of the diabetic foot ulcer (179, 180, 183, 197). Plain x-rays are indicated based on the extent and nature of the ulcer. Clinical change in the appearance of the ulcer or failure to heal with appropriate treatment may dictate repeating the radiograph periodically to monitor for osseous involvement (30). Additional imaging modalities such as nuclear medicine scans, ultrasonography, MRI, and CT may be indicated, depending on the clinical picture. These modalities have been previously discussed in this document.

Figure 6 summarizes the important elements of the overall assessment of the patient with a diabetic foot ulcer. The assessment addresses underlying pathophysiology, possible causal factors, and significant predictors of outcome (25, 49, 54, 100, 272).

### **Treatment of Diabetic Ulcers: Guiding Principles**

The primary treatment goal for diabetic foot ulcers is to obtain wound closure as expeditiously as possible. Resolving foot ulcers and decreasing the recurrence rate can

lower the probability of lower extremity amputation in the diabetic patient (30, 43, 162, 168, 295-297). The Wound Healing Society defines a chronic wound as one that has failed to proceed through an orderly and timely repair process to produce anatomic and functional integrity (288). A chronic wound is further defined as one in which the healing cascade has been disrupted at some point, leading to prolonged inflammation and failure to re-epithelialize and allowing for further breakdown and infection. Early advanced or appropriate wound care practices may be more cost-effective than standard care practices for decreasing the incidence of lower extremity amputations (43, 298).

The essential therapeutic areas of diabetic ulcer management are as follows: management of comorbidities; evaluation of vascular status and appropriate treatment; assessment of lifestyle/psychosocial factors; ulcer assessment and evaluation; tissue management/wound bed preparation; and pressure relief.

### **Management of Comorbidities**

Because diabetes is a multi-organ systemic disease, all comorbidities that affect wound healing must be assessed and managed by a multidisciplinary team for optimal outcomes in the diabetic foot ulcer (163-165, 173, 278, 299-301). Many systemic manifestations affect wound healing. Among the most common comorbidities are hyperglycemia and vascular diseases such as cerebral vascular accidents, transient ischemic attacks, myocardial infarctions, angina, valvular heart disease, atrial fibrillation, aneurysms, renal dysfunction, hypertension, hypercholesterolemia, and hyperlipidemia (48, 275, 302-304).

### **Evaluation of Vascular Status**

Arterial perfusion is a vital component for healing and must be assessed in the ulcerated patient, since impaired circulation contributes significantly to nonhealing of ulcers and subsequent risk for amputation (52, 77, 89, 214, 305). Early evaluation and referral are important (91). Symptoms of vascular insufficiency may include edema, altered skin characteristics (lack of hair, diseased nails, altered moisture), slow healing, cool or cold extremities, and impaired arterial pulsation. Vascular reconstructive surgery of the occluded limb improves prognosis and may be required prior to debridement, foot sparing surgery, and partial amputation (88, 227, 306, 307).

### **Assessment of Lifestyle/Psychosocial Factors**

Lifestyle and psychosocial factors may influence wound healing. For example, smoking has a profound effect on

**Table 6 University of Texas Classification System**

Stage	Grade			
	O	I	II	III
<b>A</b>	Pre- or post-ulcerative lesions completely epithelized	Superficial wound not involving tendon, capsule, or bone	Wound penetrating to tendon or capsule	Wound penetrating to bone or joint
<b>B</b>	Infected	Infected	Infected	Infected
<b>C</b>	Ischemic	Ischemic	Ischemic	Ischemic
<b>D</b>	Infected and ischemic	Infected and ischemic	Infected and ischemic	Infected and ischemic

wound healing due to its associated vasoconstriction and low oxygen-carrying capacity of blood (308, 309). Other factors (eg, alcohol and drug abuse, eating habits, obesity, malnutrition, and mobility and activity levels) should also be noted. In addition, depression and mental illness may impact the outcome of treatment, since these conditions can directly affect the patient’s adherence to recommendations and attitude towards healing (310, 311).

**Ulcer Assessment and Evaluation**

The importance of a thorough and systematic evaluation of any ulceration cannot be overemphasized; indeed, the findings of an ulcer-specific examination will directly guide

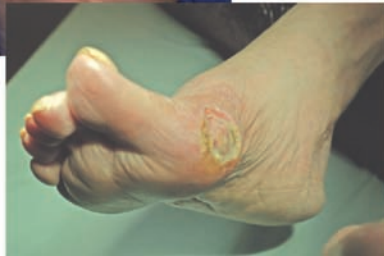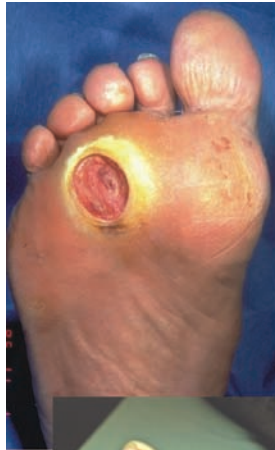subsequent treatment (25, 100). Initial evaluation and detailed description of any ulcer should encompasses location, size, depth, shape, inflammation, edema, exudate (quality and quantity), past treatment, and duration (123, 272). The margins of the ulcer should be assessed for callus formation, maceration, and erythema. The presence of erythema along with other signs such as tenderness and warmth might suggest infection (312). The quality of the tissue (ie, moist, granular, desiccated, necrotic, undermining, slough, eschar, or liquefied) should be noted (313). Thorough evaluation is used to determine the presence of sinus track or deep abscess.

**Table 7 PEDIS Ulcer Classification**

	Grade			
	1	2	3	4
<b>Perfusion</b>	Normal	Non-critical PAD	Critical limb ischemia	
<b>Extent/size (cm<sup>2</sup>)</b>				
<b>Depth tissue loss</b>	Full thickness	Deep	Bone and / or joint	
<b>Infection</b>	None	Mild	Moderate / severe	SIRS*
<b>Sensation</b>	Intact	LOPS		

\* Systemic inflammatory response syndrome





### **Skin / Ulcer**

- description, depth, location, classification

### **Infection**

- gram stain, cultures, radiographs, scans

### **Vascular**

- pulses, color, skin temperatures, Doppler, TcPO<sub>2</sub>

### **Neuropathy**

- sensory disturbances, monofilament, VPT, DTRs

### **Deformity**

- deformity, joint mobility, contractures

### **Etiology**

- mechanical, thermal, chemical

**Figure 6** Assessment of a diabetic foot ulcer includes not only a description of the skin lesion but also the findings necessary for accurate assessment of the contributing factors and etiology.

Frequent re-evaluation with response-directed treatment is essential. Once the ulcer is healed, management consists of decreasing the probability of recurrence.

#### **Tissue Management / Wound Bed Preparation**

**Debridement.** Debridement of necrotic tissue is an integral component in the treatment of chronic wounds since they will not heal in the presence of unviable tissue, debris, or critical colonization (314, 315). Undermined tissue or closed wound spaces will otherwise harbor bacterial growth (312, 316, 317). Debridement serves various functions: removal of necrotic tissue and callus; reduction of pressure; evaluation of the wound bed; evaluation of tracking and tunneling; and reduction of bacterial burden (318, 319). Debridement facilitates drainage and stimulates healing (320). However, debridement may be contraindicated in arterial ulcers (321). Additionally, except in avascular cases, adequate debridement must always precede the application of topical wound healing agents, dressings, or wound closure procedures (30, 288, 322, 323). Of the five types of debridement (surgical, enzymatic, autolytic, mechanical, biological), only surgical debridement has been proven to be efficacious in clinical trials (323).

**Surgical debridement.** Surgical debridement is the cornerstone of management of diabetic foot ulcers. Thorough sharp debridement of all nonviable soft tissue and bone from the open wound is accomplished primarily with a scalpel, tissue nippers, curettes, and curved scissors (324). Excision of necrotic tissue extends as deeply and proximal-

ly as necessary until healthy, bleeding soft tissue and bone are encountered. Any callus tissue surrounding the ulcer must also be removed. The main purpose of surgical debridement is to turn a chronic ulcer into an acute, healing wound (325). A diabetic ulcer associated with a deep abscess requires hospital admission and immediate incision and drainage (178). Joint resection or partial amputation of the foot is necessary if osteomyelitis, joint infection, or gangrene are present (41, 100, 123, 151, 180, 271). The principles guiding the surgical management of diabetic foot ulcers are discussed under "Surgical Management of the Diabetic Foot."

Necrotic tissue removed on a regular basis can expedite the rate at which a wound heals and has been shown to increase the probability of attaining full secondary closure (323, 326). Less frequent surgical debridement can reduce the rate of wound healing and secondarily increase the risk of infection. Surgical debridement is repeated as often as needed if new necrotic tissue continues to form (327). Frequent debridement, referred to as "maintenance debridement," is commonly required (328). While the terms surgical debridement and sharp debridement are often used synonymously, some clinicians refer to surgical debridement as that done in an operating room whereas sharp debridement is performed in a clinic setting (325).

Hydrosurgery (Versajet®, Smith & Nephew, Inc., London, UK) is a novel system indicated for the surgical debridement of damaged and necrotic tissue in traumatic, ulcerated, and chronic wounds, surgical incisions, and burns



(329, 330). Among its properties are precision, selective cutting, and minimal thermal damage to the tissues (331).

When surgical or sharp debridement is not indicated, other types of debridement can be used. For example, vascular wounds may benefit from enzymatic debridement, while an extremely painful wound may benefit from autolytic debridement. Mechanical debridement is often used to cleanse wounds prior to surgical or sharp debridement. In areas where the medical staff is not trained in surgical or sharp debridement, these other forms of debridement may be useful (325).

*Enzymatic debridement.* A highly selective method, enzymatic debridement consists of the application of exogenous proteolytic enzymes manufactured specifically for wound debridement. Various enzymes have been developed, including bacterial collagenase, plant derived papain/urea, fibrinolysin/DNAse, trypsin, streptokinase-streptodornase combination; only the first three products are widely available commercially (319). Collagenases are enzymes that are isolated from *Clostridium histolyticum*. These display high specificity for the major collagen types (I and II), but they not active against keratin, fat, or fibrin (312, 332, 333). Papain, obtained from the papaya plant, is effective in the breakdown of fibrinous material and necrotic tissue. When combined with urea, it denatures nonviable protein matter (312). The enzymatic compounds are inactivated by hydrogen peroxide, alcohol, and heavy metals, including silver, lead, and mercury (334). One study found that wounds treated with papain-urea developed granulation tissue faster than those treated with collagenase, but no contrasts between rates of complete wound healing were made (335).

*Autolytic debridement.* Autolytic debridement occurs naturally in a healthy, moist wound environment when arterial perfusion and venous drainage are maintained.

*Mechanical debridement.* A nonselective, physical method of removing necrotic tissue, mechanical debridement may include wet-to-dry dressings and high-pressure irrigation or pulsed lavage and hydrotherapy (30, 62, 336, 337). Wet-to-dry is one of the most commonly prescribed and overused methods of debridement in acute care settings (312, 338). Hydrotherapy in the form of whirlpool may remove surface skin, bacteria, wound exudates, and debris. There may be justification in the early stages of a wound for the use of this technique, but it is detrimental to friable granulation tissue (312, 334).

*Biological (larval) therapy.* Larval therapy utilizes the sterile form of the *Lucilia sericata* blowfly for the debridement of necrotic and infected wounds. Maggots secrete a powerful proteolytic enzyme that liquefies necrotic tissue (339-342). It has been noted that wound odor and bacterial

count, including methicillin-resistant *Staphylococcus aureus*, diminish significantly (343) with larval therapy. Larval therapy seems to be beneficial, but there is paucity of controlled studies to support its routine use in the diabetic foot wound.

**Moisture Balance.** One of the major breakthroughs in wound management over the past 50 years was the demonstration that moisture accelerates re-epithelialization in a wound (315, 344, 345). Tissue moisture balance is a term used to convey the importance of keeping wounds moist and free of excess fluids. A moist wound environment promotes granulation and autolytic processes (325). Effective management of chronic wound fluids is an essential part of wound bed preparation; it also helps in addressing the issues of cellular dysfunction and biochemical imbalance (328, 346-348).

Wound dressings can be categorized as passive, active, or interactive (349). Passive dressings primarily provide a protective function. Active and interactive dressings and therapies are capable of modifying a wound's physiology by stimulating cellular activity and growth factor release (350). An example is ORC/collagen (Promogran™, Johnson & Johnson, Inc., New Brunswick, NJ). Composed of collagen and oxidized regenerated cellulose, this bioabsorbable matrix decreases tissue destruction and prevents growth factor degradation (351, 352). Recently, silver has been added to this product (Prisma™, Johnson & Johnson, Inc., New Brunswick, NJ) to also provide an effective antibacterial barrier. Although these products are commonly used in clinical practice, they have not yet been conclusively shown to expedite wound healing. A wide variety of wound care products is available; a brief listing of dressings and topical agents is presented in Table 8.

**Inflammation and Infection.** In chronic wounds, inflammation persists due to recurrent tissue trauma and the presence of contaminants. Nonhealing wounds can become "stuck" in the inflammatory phase of healing, increasing cytokine response with subsequent elevated protease levels and impaired growth factor activity (314, 347, 352-357). The presence of infection must be ascertained and identified as local (soft tissue or osseous), ascending, and/or systemic. In diabetes, where the host response is reduced and normal signs of infection (ie, fever, pain, leukocytosis) may be absent, other factors such as elevated glucose levels can be helpful as an indicator of infection (41, 358). It is important to obtain specimens for culture prior to antimicrobial therapy. Tissue specimens collected by curettage or biopsy are preferred, because they provide more accurate results than superficial swabs (287).

Table 8

## Wound Care Products

Category	Indications	Contraindications
<b>Dressings</b>		
<b>Gauze pads</b> (312, 338, 352) - sterile gauze - sterile cotton	- Low to heavily draining wounds or surgical wounds - Wet to dry debridement	- Undefined
<b>Transparent films</b> (312, 352) - polyurethane film with drainage adhesive layer, semipermeable	- Dry to minimally draining wounds - Promote tissue hydration	- Infection - Significant drainage - Over prominence or friction
<b>Hydrogels</b> (312, 352) - gel, sheet, gauze (95% water or glycerin)	- Dry to minimally draining wounds	- Moderate or heavy drainage
<b>Foam</b> (312, 352) - polyurethane foam (open cell, absorbent)	- Moderate, large exudate - Clean wound surface - Super absorbent and conformable to topography	- Dry wounds
<b>Hydrocolloids</b> (312, 352) - wafer with adhesion, (carboxymethylcellulose, pectin, gelatin) impermeable to oxygen	- Low to moderate drainage * Prevents tissue hydration	- Heavy drainage - Sinus tract
<b>Calcium alginates</b> (312, 352) - fiber pad derived from seaweed (may be combined with silver or collagen)	- Heavy exudative wounds	- Minimal drainage or dry wounds
<b>Collagen dressings</b> (302, 312, 325, 352) - particles or composite pads with collagen component (derived from bovine collagen)	- Low to heavily draining wounds	- Dry wounds
<b>Antimicrobial dressings</b> (312, 334, 352) - contain silver, iodine in various forms preparations (eg, cadoximer iodine)	- Infected or clean wounds to prevent infection	- Allergies to components
<b>Topical Therapies / Agents</b>		
<b>Saline</b> (302, 352) <b>Amorphous hydrogels</b> <b>Skin cleansers</b> - isotonic solutions for irrigation, hydrating dressings	- Clean or infected wounds	- Undefined
<b>Detergents/Antiseptics</b> (302, 352) - povidone-iodine, - chlorhexidine - chloroxylenol - hypochlorite - benzethonium chloride	- Contaminated or infected wounds	- Healthy granulating wounds
<b>Topical Antibiotics</b> (302, 320, 352) - bacitracin, neomycin - mupirocin, polymyxin B - silver sulfadiazine - mafenide (creams, ointments)	- Contaminated or infected wounds	- Healthy granulating wounds
<b>Enzymes</b> (302, 312, 319, 328, 332-335) - collagenase - papain-urea	- Necrotic tissue - Escharotic wounds	- Healthy or infected wounds

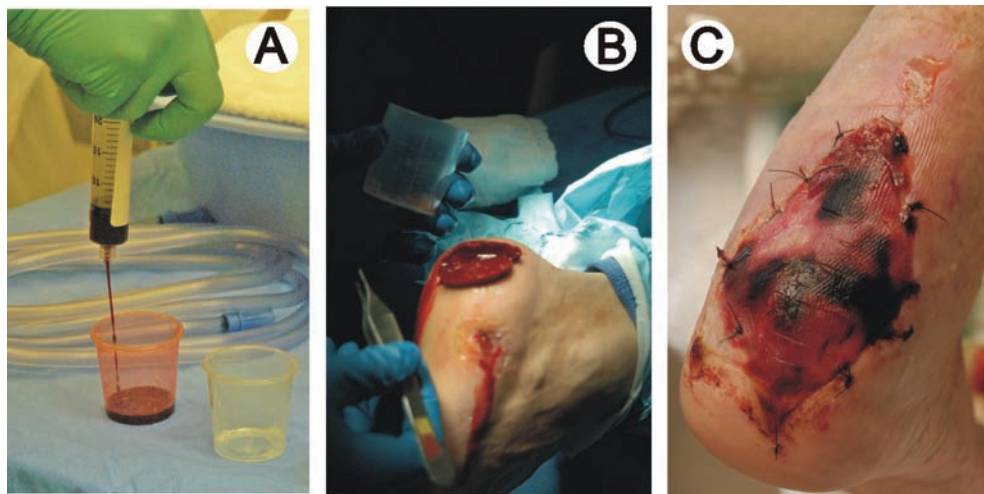
**Advanced Wound Care Modalities.** Wound bed preparation offers clinicians a comprehensive approach to removing barriers to healing and stimulating the healing process so that the benefits of advanced wound care can be maximized (314, 359). Advanced care may sometimes be the only means of rapidly and effectively attaining wound closure (360). The advent of therapeutic growth factors, gene therapy, tissue-engineered constructs, stem cell therapy, and other drugs and devices that act through cellular and molecular-based mechanisms is enabling the modern surgeon and wound-care provider to actively promote wound angiogenesis to accelerate healing (361-363).

*Growth factor therapy.* Chronic ulcers have demonstrated benefit from autologous platelet releasates or genetically-engineered products such as recombinant DNA platelet-derived growth factor becaplermin gel (Regranex™, Johnson & Johnson, Inc., New Brunswick, NJ) (361, 362, 364). This agent has been shown to stimulate chemotaxis and mitogenesis of neutrophils, fibroblasts, monocytes and other components that form the cellular basis of wound healing (326, 365-368). In one pivotal randomized placebo-controlled blinded trial involving patients with full thickness diabetic foot ulcers, recombinant human platelet-derived growth factor (becaplermin) demonstrated a 43% increase in complete closure versus placebo gel (50% vs 35%) (362). Other growth factors, including vascular

endothelial growth factor (VEGF), fibroblast growth factor (FGF), and keratinocyte growth factor (KGF), have been under study but are not yet approved for use in the US.

Autologous platelet-rich plasma treatments (Fig. 7) utilize the patient's own blood to create a gel that is applied to the wound (364). Activation of the plasma after centrifugation stimulates the release of multiple growth factors from the platelet's alpha granules and the conversion of the plasma fibrinogen to a fibrin matrix scaffold. Both actions may assist with new tissue formation. A large retrospective study reviewing this treatment protocol in commercial wound healing centers suggested a benefit in healing larger, more severe neuropathic ulcerations (369).

*Bioengineered tissues.* Bioengineered tissues have been shown to significantly increase complete wound closure in venous and diabetic foot ulcers (370-374). Currently, two bioengineered tissues have been approved to treat diabetic foot ulcers in the US: Apligraf™ (Organogenesis Inc., Canton, MA), and Dermagraft™ (Smith & Nephew, Inc., London, UK); both have demonstrated efficacy in randomized, controlled trials. Tissue-engineered skin substitutes can provide the cellular substrate and molecular components necessary to accelerate wound healing and angiogenesis. They function both as biologic dressings and as delivery systems for growth factors and extracellular matrix components through the activity of live human fibroblasts contained in their dermal elements (370, 375).



**Figure 7** New technologies have been developed that have proved useful for management of diabetic ulcerations. (A) Platelet-rich plasma (PRP) involves use of the patient's blood, which is collected and then fractionated through centrifugation. A platelet-rich and platelet-poor supernatant remains. (B) This case involved use of autologous platelet-rich plasma gel activated with thrombin and placed onto a healthy wound bed. (C) The platelet gel or clot may also be covered with a synthetic skin graft substitute.

Bilayered skin substitutes (living cells) include bilayered skin equivalent (Apligraf<sup>TM</sup>) and cultured composite skin (OrCel<sup>TM</sup> bilayered cellular matrix, Ortech International, Inc., New York City, NY). Apligraf<sup>TM</sup> has been shown to significantly reduce the time to complete wound closure in venous and diabetic ulcers (371, 376). Dermagraft<sup>TM</sup> is no longer available in the US.

Extracellular matrices (nonliving) are generally derived from devitalized tissue to produce an immunologically inert acellular dermal matrix. These include dermal regeneration template (Integra<sup>TM</sup>, Integra LifeSciences Holdings Corp., Plainsboro, NJ), allogenic dermal matrix (AlloDerm<sup>TM</sup>, LifeCell, Branchburg, NJ), matrix of human dermal fibroblasts (TransCyte<sup>TM</sup>, Smith & Nephew, Inc., London, UK), and porcine small intestine submucosa (Oasis<sup>TM</sup>, Healthpoint, Fort Worth, TX). Oasis<sup>TM</sup>, composed of structural cellular components and growth factors utilized to promote natural tissue remodeling (377, 378), recently completed a randomized trial that showed non-inferiority to becaplermin gel in the healing of diabetic foot ulcers (379). Integra<sup>TM</sup> dermal regeneration template, a collagen-chondroitin sponge overlaid with silicone originally developed for burns, has been shown to be ideally suited to chronic and pathologic wounds (380).

**Adjunctive Modalities.** Regenerative tissue matrix (GraftJacket<sup>TM</sup>, Wright, Arlington, TN) is a new therapy used in diabetic foot ulcers, although it has not undergone any randomized clinical trials to date (381). This allograft skin is minimally processed to remove epidermal and dermal cells while preserving the bioactive components and structure of dermis. This results in a framework that supports cellular repopulation and vascularization.

Hyperbaric oxygen therapy (HBO) has shown promise in the treatment of diabetic foot wounds with hypoxia severe enough to interfere with healing (382-387). However, most of the HBO studies were hampered by methodological errors that preclude any definite role for this modality in the routine treatment of diabetic foot ulcers (382, 388, 389). Nevertheless, in 2003, Medicare and Medicaid coverage for HBO extended to ulcers classified as Wagner grade 3 or higher that failed standard wound care therapy. Clearly, a large multicenter randomized clinical trial is needed to properly test the efficacy of this expensive modality (388).

Several new ultrasound devices are being used to both debride the wound and provide ultrasonic therapy. The MIST Therapy<sup>TM</sup> system (Celleration<sup>TM</sup>, Eden Prairie, MN) is an ultrasonic device approved by the Food and Drug Administration (FDA) for wound debridement and cleansing. MIST Therapy<sup>TM</sup> uses a fine saline spray that allows ultrasound to be administered directly to the wound bed without contact to the affected tissue, thus minimizing

potential trauma to delicate capillary buds and emerging islands of epithelium (390-392).

Negative pressure wound therapy (NPWT) has become a common adjunctive treatment modality for diabetic foot ulcerations (393-397). Use of a vacuum-assisted closure<sup>®</sup> device (V.A.C.<sup>®</sup>, KCI, San Antonio, TX) promotes wound healing through the application of topical, subatmospheric, or “negative” pressure to the wound base (398, 399). This therapy removes edema and chronic exudate, reduces bacterial colonization, enhances formation of new blood vessels, increases cellular proliferation, and improves wound oxygenation as the result of applied mechanical force. These actions are synergistic (400, 401). Numerous applications of this modality have proven successful, including use over exposed bone, tendons, and hardware to generate granulation tissue (394, 395, 402-405). It is also frequently used to facilitate adherence of split thickness skin grafts, rotational flaps, or tissue substitutes to a wound bed (396, 406-409). A recent clinical trial of the V.A.C.<sup>®</sup> device for the treatment of open amputation wounds in the diabetic foot showed significantly faster healing and development of granulation tissue with NPWT compared with standard moist wound care (410).

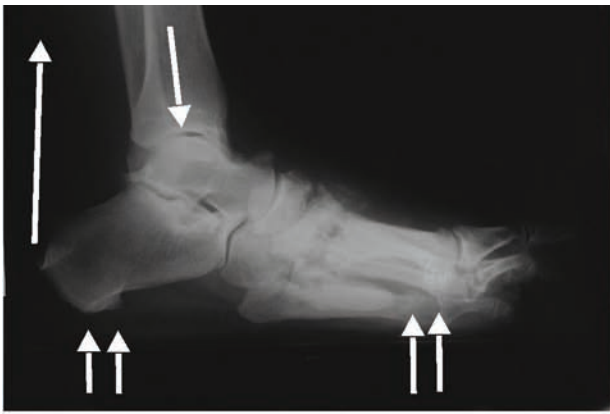
The rationale for using electrical stimulation in wound healing stems from the fact that the human body has an endogenous bioelectric system that enhances healing of bone fractures and soft tissue wounds. Laboratory and clinical studies provide an abundance of support for the use of electrical stimulation in wound care (411, 412). In a randomized, controlled study evaluating wound healing using electrical stimulation in neuropathic ulcers, significant differences in healed ulcer areas and number of healed ulcers at 12 weeks were found in the group receiving electrical stimulation compared with the control group (413).

### Pressure Relief/Off-loading

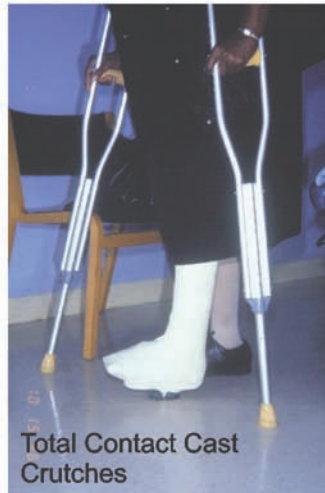The reduction of pressure to the diabetic foot ulcer is essential to treatment (26, 76, 80, 107, 414-417). Proper off-loading and pressure reduction prevents further trauma and promotes healing. This is particularly important in the diabetic patient with decreased or absent sensation in the lower extremities (50, 418). Furthermore, recent studies provide evidence that minor trauma (eg, repetitive stress, shoe pressure) plays a major role in the causal pathway to ulceration (24). A list of off-loading modalities is presented in Figure 8.

The choice of off-loading modality should be determined by the patient's physical characteristics and ability to comply with treatment as well as by the location and severity of the ulcer. Various health care centers prefer specific initial modalities, but frequently clinicians must alternate treat-





- Total nonweightbearing: crutches, bed rest, wheelchair
- Total contact casting
- Foot casts or boot
- Removable walking brace with rocker bottom sole
- Total contact orthoses - custom walking braces
- Patella tendon-bearing braces
- Half shoes or wedge shoes
- Healing sandal - surgical shoe + molded plastazote foot bed
- Accommodative dressings: felt, foam, felted foam
- Shoe cutouts - toe box, medial, lateral, dorsal pressure points
- Assistive devices: crutches, walker, cane



**Figure 8** Diabetic foot ulcers are most often located under weightbearing areas of the foot. Essentials of management include “off-loading” of the foot or area of ulceration. Healed ulcers may be managed with shoes and variations of molded or multiple density insoles, while the total contact cast remains the standard approach to off-loading areas of ulceration.

ments based on the clinical progress of the wound. Even as simple a method as a felted foam aperture pad has been found to be effective in removing pressure and promoting healing of foot ulcers (419-421). A study published in 2001 noted that use of a total contact cast (TCC) healed a higher portion of wounds in a shorter time than a half shoe or removable cast walker (RCW) (414). More recently, investigators compared TCC use with that of a removable cast walker that was rendered irremovable (iTCC) by circumferential wrapping of an RCW with a single strip of fiberglass casting material. They concluded that the latter may be equally efficacious, faster to place, easier to use, and less expensive than TCC in the treatment of diabetic neuropathic plantar foot ulcers (422). The findings of this study and another study also suggest that modification of the RCW into an irremovable device may improve patient compliance, thereby increasing the proportion of healed ulcers and

the rate of healing of diabetic neuropathic wounds (417).

Regardless of the modality selected, no patient should return to an unmodified shoe until complete healing of the ulcer has occurred (30, 77, 90, 255). Furthermore, any shoe that resulted in the formation of an ulcer should never again be worn by the patient.

### Wounds That Fail to Heal

Wounds that do not respond to appropriate care, including debridement, off-loading, and topical wound therapies, must be reassessed. Infection and ischemia are especially important considerations and common reasons for failure to heal.

The presence of infection must be determined and identified as either soft tissue, osseous, or both. Excessive bioburden can be indicated by pale or friable granulation tissue, persistent drainage, or fibrinous surface layer (314).



**Table 9 Factors Favoring Wound Chronicity (426)**

- 
- |  |  |
|--|--|
| <ul style="list-style-type: none"><li>● Nutritional deficiency<ul style="list-style-type: none"><li>- Protein calorie</li><li>- Vitamins</li><li>- Minerals</li></ul></li><li>● Tissue hypoxia<ul style="list-style-type: none"><li>- Ischemia</li><li>- Venous insufficiency</li><li>- Edema</li></ul></li><li>● Infection / bioburden</li><li>● Metabolic<ul style="list-style-type: none"><li>- Diabetes</li><li>- Chronic renal insufficiency</li></ul></li><li>● Malignancy</li></ul> | <ul style="list-style-type: none"><li>● Immune compromise<ul style="list-style-type: none"><li>- Immunosuppressive drugs</li><li>- Steroids</li></ul></li><li>● Mechanical<ul style="list-style-type: none"><li>- Pressure</li><li>- Shear</li><li>- Friction</li><li>- Repetitive injury</li></ul></li><li>● Miscellaneous<ul style="list-style-type: none"><li>- Inadequate debridement</li><li>- Toxic wound care products</li><li>- Radiation therapy</li><li>- Aging / debility</li></ul></li></ul> |
|--|--|
- 

Indicators for frank infection will also include pain (especially in the neuropathic patient), erythema, and induration. When bone or joint is visible or palpable at the depth of the ulcer, osseous infection becomes more likely (285, 423). A thorough discussion of the management of infected wounds is presented later in this document and summarized in Pathway 4.

Unrecognized ischemia will also impair wound healing and must be diagnosed prior to development of infection or ischemic necrosis of the ulcer. When no progress or enlargement of the wound has taken place, re-examination of the vascular status of the extremity is warranted (Pathway 2). This should include arterial Doppler segmental pressures with waveforms, digital arterial pressures, or measurement of transcutaneous oxygen partial pressures (TcPO<sub>2</sub>) (52, 212). Vascular surgical consultation should also be considered for further evaluation and treatment.

Other parameters critical to wound healing should also be addressed, including the need for further debridement or a change in off-loading modality. Nonadherence to prescribed treatments or off-loading can be especially problematic in patients with peripheral neuropathy (424, 425). Additional concerns may include renal insufficiency, biochemical imbalances, chronic anemia, nutritional deficiencies, or ulceration due to nondiabetic etiologies (ie, radiation, malignancy, etc) (354, 426). Biopsy of chronic, nonhealing wounds should always be considered. Table 9 summarizes the range of possible impediments to wound healing.

#### **DIABETIC FOOT INFECTIONS (Pathway 4)**

Foot infection is a major reason for hospitalization among patients with diabetes and also an important causal factor for lower limb amputation (122, 151, 427). There are various presentations of diabetic foot infections as well as several ways to classify these entities. (428)

#### **Classification of Diabetic Foot Infections**

Foot infections may be described in terms of severity, extent of involvement, clinical appearance, location, and etiology. Any system for classifying these infections should also serve to facilitate management and predict outcomes. One well accepted method simply provides two categories: non-limb-threatening and limb-threatening infections (30, 41, 77, 151, 177, 429). This scheme implies severity of infection and, accordingly, directs subsequent management while also portending a general prognosis for outcome.

Clinically, non-limb-threatening infections are usually seen with ulceration that is superficial, without significant ischemia, and a wound that does not probe to bone or joint (41). Ulceration, however, does not need to be present, since non-limb-threatening infections can result from small puncture wounds, scratches, or simple fissures. Cellulitis in this category of infections is 2 cm or less from the ulceration or portal of entry. Patients with non-limb-threatening infections are medically stable and usually do not present with signs and symptoms of systemic involvement. This relatively mild to moderate infection can be managed on an outpatient basis, with close supervision from the clinician (30, 430).

Limb-threatening diabetic foot infections have cellulitis that extends beyond 2 cm (430). Additional clinical features may include fever, edema, lymphangitis, hyperglycemia, leukocytosis, and ischemia; however, the diabetic patient with a relatively severe infection may not necessarily present with these signs and symptoms (178). If an ulcer is present it may probe to bone or joint, which is highly predictive of osteomyelitis (285). Therefore, it is important to review the patient's entire clinical assessment (see Table 3) to guide the clinician to the proper course of treatment. Gangrene, abscesses, osteomyelitis, and necrotizing fasciitis may also

**PATHWAY #4**

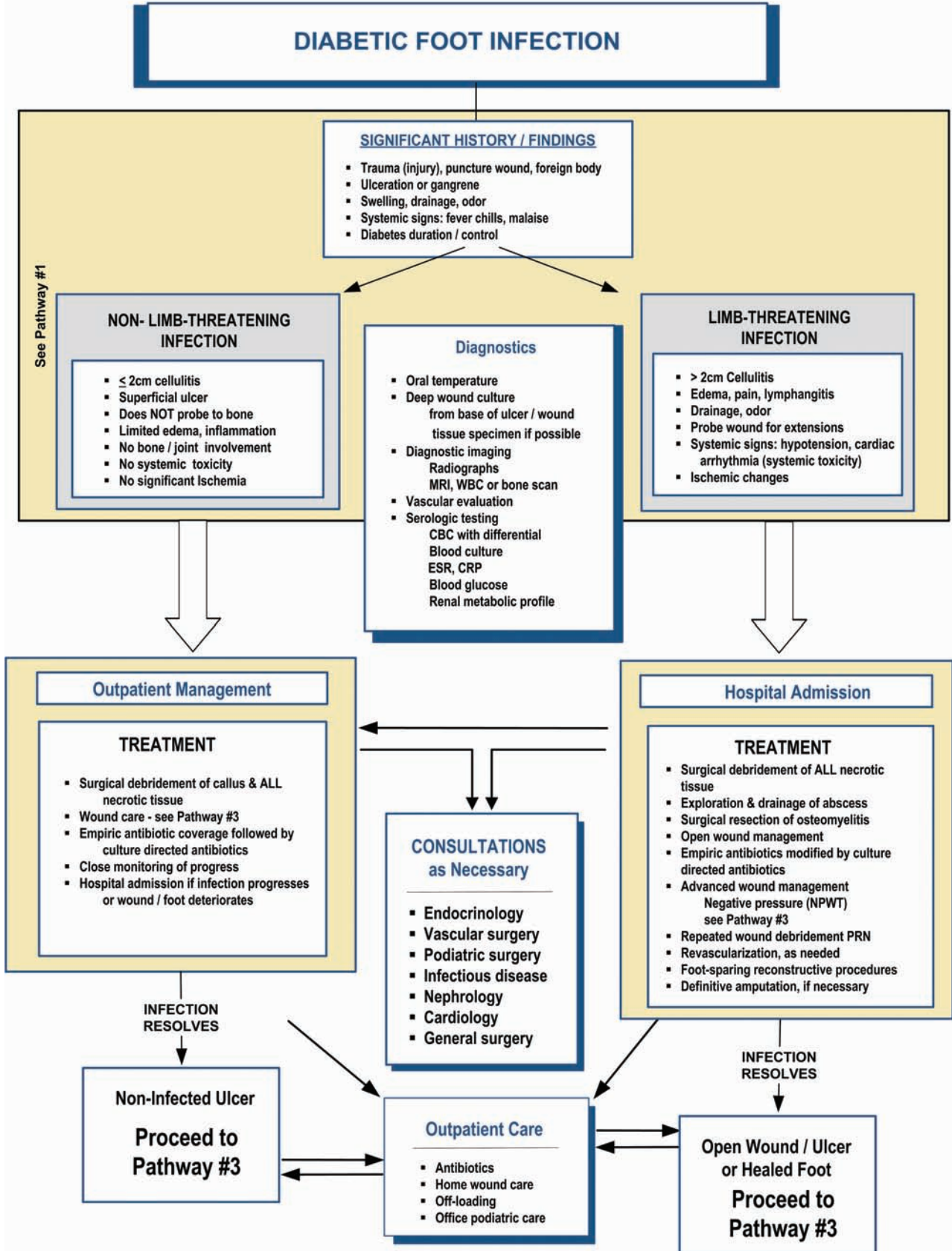


Table 10

## IDSA Guidelines for the Clinical Classification of Diabetic Foot Infections

Clinical Evidence of Infection	Infection Severity	PEDIS Grade
Wound lacking purulence or any manifestations of inflammation	Uninfected	1
Presence of $\geq 2$ manifestations of inflammation (purulence, erythema, pain, tenderness, warmth, or induration), but cellulitis/erythema extends $\leq 2$ cm from margins of ulcer, and infection is limited to the skin or superficial subcutaneous tissues; no other local complications or systemic illness	Mild	2
Infection (as above) in a patient who is systemically well and metabolically stable but has 1 of the following characteristics: cellulitis extending $> 2$ cm, lymphangitic streaking, spread beneath the superficial fascia, deep-tissue abscess, gangrene, and involvement of muscle, tendon, joint, or bone	Moderate	3
Infection in a patient with systemic toxicity or metabolic instability (eg, fever, chills, tachycardia, hypotension, confusion, vomiting, leukocytosis, acidosis, severe hyperglycemia, or azotemia)	Severe	4

be present. Hospitalization is required to treat the infection as well as systemic sequelae. Patients with poor vascular status and ischemia have an increased potential for amputation and require prompt consultation for potential revascularization (30, 77, 200).

In 2004, the Infectious Disease Society of America (IDSA) developed new guidelines for the diagnosis and treatment of diabetic foot infections (123). The guidelines incorporate the infection portion of the PEDIS system into IDSA's preferred clinical classification for infections in the diabetic foot (Table 10).

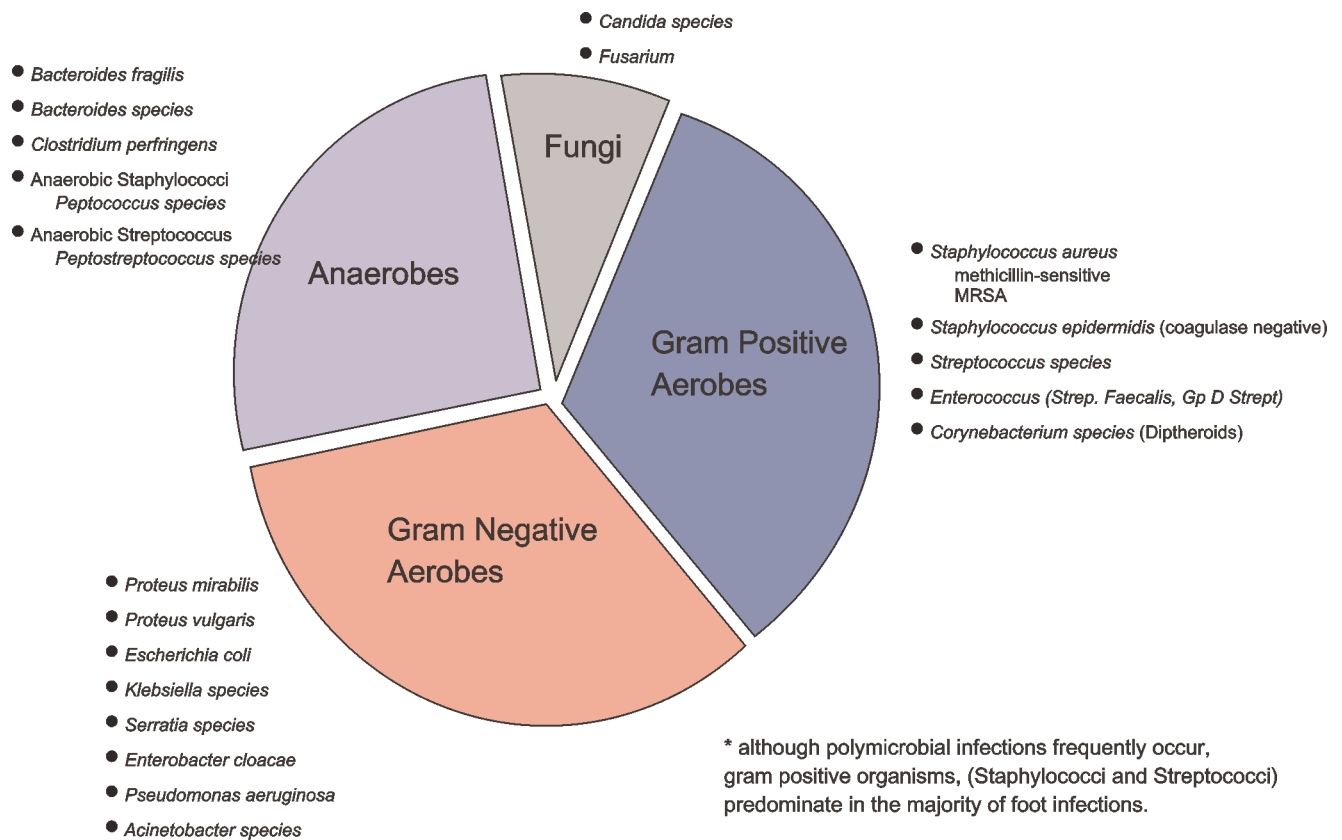
### Assessment of Diabetic Foot Infections

When evaluating the patient with a diabetic foot infection, a problem-directed history and physical examination should be obtained. A systematic approach to the complete assessment of these patients is required, since there is evidence that they are often inadequately evaluated, even when hospitalized (431). The past medical history should assess the patient's neurologic, cardiovascular, renal, and dermatologic status. Use of current medications as well as previous antibiotics may interfere with planned treatments or indicate that standard treatments will likely be ineffective. Pain should be considered an unreliable symptom in individuals with peripheral neuropathy. The patient should be ques-

tioned regarding previous ulcerations, infections, trauma, and surgeries at the present site or at any other past location of infection.

Constitutional symptoms (eg, nausea, malaise, fatigue, vomiting, fever, chills) are important clinical clues when presented with an infected diabetic foot. Severe infection or sepsis must be considered when these symptoms are present. However, in about 50% of diabetic patients presenting with significant infection, systemic signs (fever and leukocytosis) are absent (178). Frequently, the only indication of infection is unexplained or recalcitrant hyperglycemia. Laboratory testing might include a CBC with or without differential, blood cultures, glycosylated hemoglobin, fasting blood sugar, sedimentation rate, and urinalysis. Other tests should be performed as indicated by the patient's condition or comorbidities.

The history of the wound or infection should include the onset, duration, and appearance before infection of the area. Depth or size of the ulcer, amount of drainage, swelling, color, odor, and extent of infection should be evaluated. The infection or ulcer should be probed to determine the presence of bone or joint involvement, sinus tracts, or extension into tendon sheaths. The latter are common routes for the spread of infection both distally and proximally. Reliable aerobic and anaerobic cultures should be obtained from



**Figure 9** Diabetic foot infections are generally considered polymicrobial, because multiple organisms are frequently found in a wound milieu. *Staphylococcus* and *Streptococcus* remain the most important organisms causing infection.

purulent drainage or curettage of the ulcer base, since studies have shown good concordance with the true pathogen (116, 428, 432). Simple swab cultures of an ulcer surface are generally not advisable because they tend to be unreliable, especially in the presence of osteomyelitis or sinus tracts (123, 433, 434).

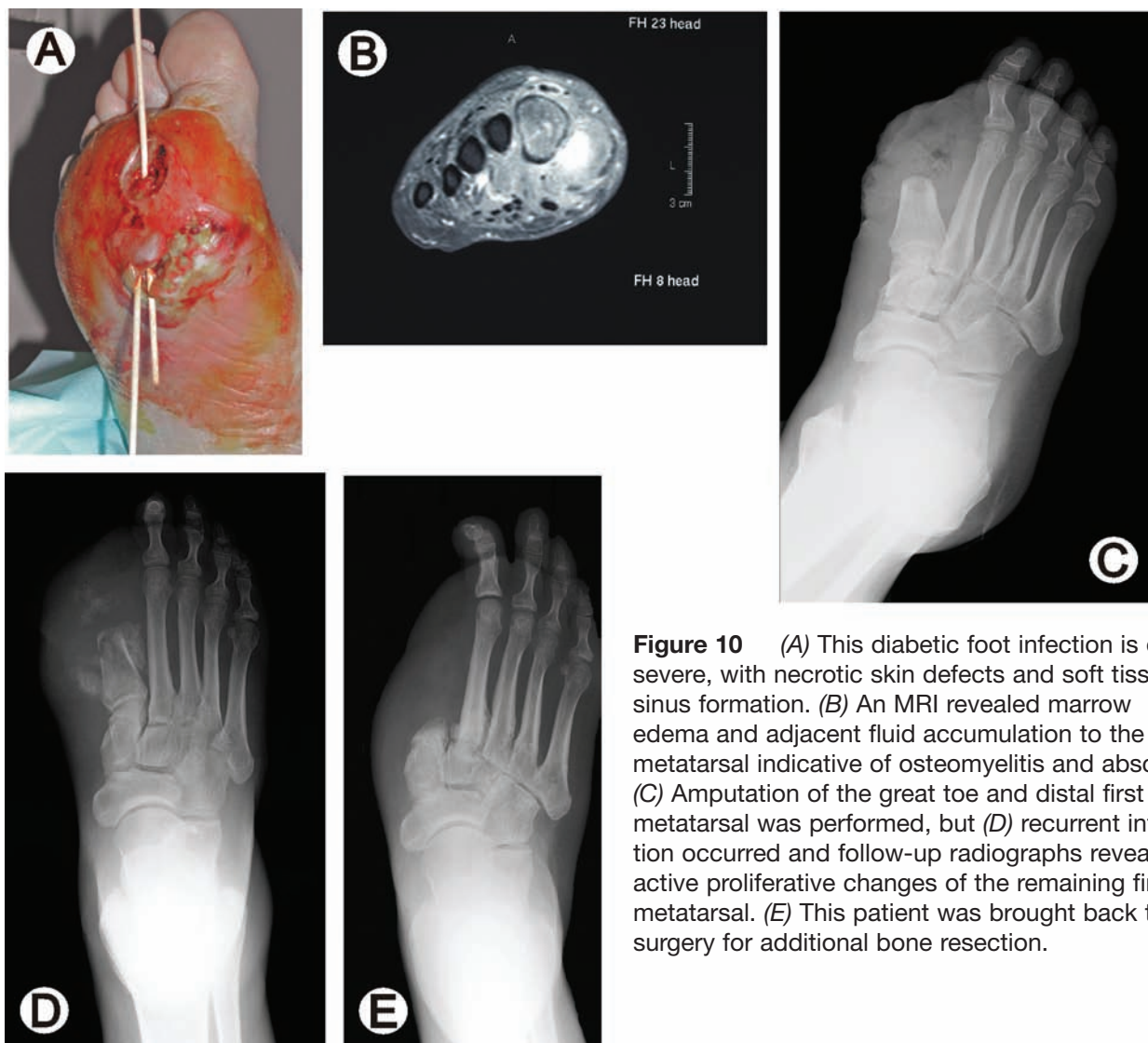
For patients with clinically uninfected or noninflamed neuropathic ulcers, the role of antibiotic therapy is still in question (30). Therefore, in these instances, wound culture is probably unnecessary (123). If osteomyelitis is suspected, bone cultures are necessary to make the definitive diagnosis and isolate the true pathogen (180, 435, 436). However, this must be balanced against the potential for contaminating noninfected bone in the presence of an active soft tissue infection. Intraoperative frozen section is also useful in assessing for deep infection. The presence of more than 5 to 10 neutrophils per high power field is suggestive of acute infection (437).

The majority of wounds are caused by *Staphylococcus aureus*, beta-hemolytic streptococci, and other gram positive cocci (Fig 9) (151, 438, 439). Although community-acquired cases of resistant bacterial infections have been

reported, patients who have been previously hospitalized with an open wound are more likely to develop an infection from resistant bacteria such as methicillin-resistant *S aureus* (MRSA) and vancomycin-resistant enterococci (VRE) (440). Chronic wounds may develop a more complex assortment of bacteria, including gram negative rods, obligate anaerobes, *Pseudomonas aeruginosa*, and enterococci.

Imaging studies are also important in the overall assessment of diabetic foot infections, notwithstanding their shortcomings. Plain film x-rays may indicate the presence of bony erosions and/or gas in the soft tissues. It should be noted that the demonstration of osteomyelitis by plain radiographs lags the onset of bone involvement by 10 to 14 days (180, 197). Radionucleotide bone scans such as Tc-99 may demonstrate abnormal uptake of the radionucleotide before changes are visible on radiographs (179). This may be less specific in patients with peripheral neuropathy or with any preexisting osseous condition that causes increased bone turnover (eg, surgery, fracture, neuropathic arthropathy) (441). A combination of scans such as the Tc-99m and an indium-labeled leukocyte scan or the Tc-99m HMPAO-labeled leukocyte scan may aid the clinician in differentiat-





**Figure 10** (A) This diabetic foot infection is quite severe, with necrotic skin defects and soft tissue sinus formation. (B) An MRI revealed marrow edema and adjacent fluid accumulation to the first metatarsal indicative of osteomyelitis and abscess. (C) Amputation of the great toe and distal first metatarsal was performed, but (D) recurrent infection occurred and follow-up radiographs revealed active proliferative changes of the remaining first metatarsal. (E) This patient was brought back to surgery for additional bone resection.

ing Charcot arthropathy and osteomyelitis with greater accuracy (185, 186, 203). MRI has generally supplanted the CT scan in the early diagnosis of osteomyelitis (Fig 10), due to its higher tissue contrast and ability to detect both soft tissue and marrow inflammation (183, 200, 202, 442). Additionally, MRI can be used to follow the resolution of infection or as an aid in surgical planning (201, 443). However, none of these imaging modalities are 100% sensitive and specific for diagnosing or ruling out bone infection. Furthermore, these tests are expensive and may not be readily available. Appropriate clinical assessment and diagnostic acumen should therefore remain the guiding principles to management.

### Treatment of Diabetic Foot Infections

Diabetic foot infections should be managed through a multidisciplinary team approach utilizing appropriate con-

sultations (173, 178, 300). Hospitalization of patients with limb-threatening infections is mandatory. All diabetic foot infections must be monitored closely. Equally important for the best possible outcome are patient compliance and education, especially in outpatient management.

### Treatment of Non-Limb-Threatening Infections

Treatment of diabetic foot infections is guided by the severity of the infection. As previously discussed, non-limb-threatening infections involve superficial ulcerations without significant ischemia and they do not involve bone or joint (430). Typically, cellulitis does not extend 2 cm beyond the ulcer margins and there is an absence of systemic symptoms (e.g. fever, chills, nausea, vomiting). These less severe infections that frequently complicate diabetic foot ulcers, may be initially treated in an outpatient setting (41, 438, 444). Many mild or moderate infections are



monomicrobial, with *S aureus*, *S epidermidis*, and streptococci the most common pathogens (119, 121, 439). Reliable specimens for cultures may be obtained through curettage of the infected ulcer (120, 123, 445, 446). In addition to the standard treatment for ulcerations (ie, nonweightbearing and dressing changes), oral antibiotic therapy is usually sufficient as initial therapy (Table 11). Antimicrobial treatment should be started as soon as possible with an agent providing adequate gram positive coverage, recognizing that gram negative organisms might also be involved (287, 438, 439). Although the incidence of MRSA infections has increased dramatically in the past several years, methicillin-sensitive *S aureus* (MSSA) remains the most likely pathogen in community-acquired diabetic foot infections (123, 447). Therefore, initial antibiotic coverage must be tailored to cover MSSA, unless a reliable culture and sensitivity is available or there is a history of other pathogens (eg, MRSA, *Pseudomonas*, enterococcus) that require specific

coverage. Antibiotics should be adjusted according to culture results and the patient's response to treatment.

While many useful oral antimicrobial agents (eg, cephalexin, clindamycin, amoxicillin/clavulanate, levofloxacin) are available for managing mild to moderate diabetic foot infections, relatively few have been studied or have demonstrated superiority in prospective randomized clinical trials (123). Therefore, IDSA guidelines contain no specific recommendations for antimicrobial regimens in the management of diabetic foot infections.

All antibiotic treatments should be monitored for development of resistance. Most cases of cellulitis respond within 3 to 5 days of initiation of appropriate antibiotics. If cellulitis is slow to respond, worsens, or recurs following several days of treatment, the ulceration should be reassessed and possibly recultured. Bacteria frequently develop resistance to an antimicrobial agent, especially with prolonged therapy. This is not uncommon with the quinolones.

**Table 11 Empiric Antibiotic Therapy: Diabetic Foot Infections**

<b>Limb-Threatening</b>	<b>Life-Threatening</b>
<ul style="list-style-type: none"> <li>● Ampicillin / Sulbactam</li> <li>● Ticarcillin / Clavulanate</li> <li>● Piperacillin / Tazobactam</li> <li>● Ceftazidime + Clindamycin</li> <li>● Cefotaxime ± Clindamycin</li> <li>● Fluoroquinolone + Clindamycin</li> <li>● Vancomycin + Levofloxacin + Metronidazole</li> <li>● Linezolid</li> <li>● Imipenem / Cilastatin</li> <li>● Ertapenem</li> <li>● Tigecycline</li> </ul>	<ul style="list-style-type: none"> <li>● Ampicillin / Sulbactam + Aztreonam</li> <li>● Piperacillin / Tazobactam + Vancomycin</li> <li>● Vancomycin + Metronidazole + Ceftazidime</li> <li>● Imipenem / Cilastatin</li> <li>● Fluoroquinolone + Vancomycin + Metronidazole</li> <li>● Ertapenem</li> <li>● Tigecycline</li> </ul>
<b>Non-Limb-Threatening *</b>	
<ul style="list-style-type: none"> <li>● Cephalosporin (Cephalexin, Cefadroxil, Cefdinir)</li> <li>● Fluoroquinolones (Levofloxacin, Moxifloxacin, Gatifloxacin)</li> <li>● Penicillins (Dicloxacillin, Amoxicillin/Clavulanate)</li> <li>● Linezolid</li> <li>● Trimethoprim / Sulfamethoxazole</li> <li>● Doxycycline</li> </ul>	
<p>* Generally oral agents are utilized for non-limb-threatening infections as most are treated outpatient.</p>	

Superinfection can also develop when antibiotics select out opportunistic organisms, as in the case of *Pseudomonas* or yeast (*Candida* sp). Because MRSA infections have become increasingly more common pathogens and are associated with prior antimicrobial exposure (447, 448), patients with clinical infection and a prior history of MRSA should be considered to have the same pathogen until proven otherwise and treated accordingly.

Antimicrobial therapy alone is not sufficient for treating infections associated with foot ulcers (272, 449, 450). The wound should be assessed and cleansed thoroughly, using proper debridement as indicated. While there are several topical antimicrobial agents that can be used on the infected wound, there is little data on topical treatment (287). Therefore, such therapy at present can only be considered adjunctive to systemic antimicrobial therapy.

The wound should be managed according to the principles discussed previously. Most importantly, the patient should be reassessed within 48 to 72 hours. If no improvement is noted, hospitalization with intravenous antibiotics should be considered. Management of this type of infection should also include close monitoring of the patient's hyperglycemia and general health status. Patient compliance as well as a reduction in the pressure of the infected limb must be considered early on in the treatment of any diabetic foot infection (77, 451).

### Treatment of Limb-Threatening Infections

By definition, limb-threatening infections are much more serious and more often acute compared with the milder non-limb-threatening infections. In the PEDIS system (Table 10), limb-threatening infections are classified as grade 3 or 4, depending on severity and the presence of systemic manifestations (122, 123, 452). Neuropathy often predisposes such infections to progression to an emergent situation before the patient even becomes aware of the infection's presence. Limb-threatening infections may have life-threatening complications, especially when left untreated. Because of diabetes-associated immunosuppression, up to 50% of patients with limb-threatening infections may exhibit no systemic symptoms or leukocytosis (118, 178, 453). However, other patients present with evidence of systemic toxicity, including fever, chills, loss of appetite, and malaise. Such findings in diabetic patients should alert clinicians to the severity of infection. Most will note uncontrollable hyperglycemia despite usual therapy and loss of appetite (41, 454).

Limb-threatening infections are recognized as having one or more of the following findings: greater than 2 cm of cellulitis around an ulcer, lymphangitis, soft tissue necrosis,

fluctuance, odor, gangrene, osteomyelitis (30, 77, 430). When such an infection is recognized, the patient requires emergent hospital admission for appropriate intervention (116, 200, 272). Upon admission, a complete history and physical examination are undertaken. The patient's cardiovascular, renal, and neurologic risks should be evaluated to assess for secondary complications of diabetes and associated comorbidities. A thorough foot evaluation is undertaken to determine the clinical extent of the infectious process. Vascular status must be assessed to ensure that appropriate arterial inflow is present. If perfusion is inadequate, this should be addressed prior to definitive reconstruction to enhance healing at a more distal level.

Radiographs are necessary to evaluate for evidence of osteomyelitis or soft tissue gas. If gas is identified in the ankle or hindfoot, radiographs of the lower leg should be obtained to assess the extent of the gas formation. Blood cultures are required if clinical findings indicate septicemia. Other appropriate laboratory studies, including CBC with differential and sedimentation rate, are obtained as warranted. Glucose management must be initiated to optimize metabolic perturbations and improve leukocyte function (455). The patient's nutritional and metabolic status must be assessed and properly maintained, since relatively common nutritional and metabolic impairments in these patients can adversely affect wound healing and resolution of infection (314, 456, 457).

Consultations are typically required in the risk assessment and management of these complex cases. Medical, endocrinology, cardiology, nephrology, and diabetic teaching nurse consultations are often routinely needed to optimize patient care and fully assess surgical risks (181, 429). Infectious disease and vascular surgery consultations are also obtained when complex infections or significant ischemia are identified, respectively. A multidisciplinary approach to the management of these cases has been shown to significantly improve outcomes (163, 165, 173, 278, 300, 458-461).

Early surgical treatment of the affected site is typically necessary as an integral part of infection management (178, 451, 460, 462). This may include simple debridement of the soft tissues, wide incision and drainage of the pedal compartments, or open amputation to eliminate extensive areas of infection (124, 463, 464). At the time of debridement, aerobic, anaerobic, and fungal tissue cultures should be obtained from the depth of the wound to provide reliability (287, 432, 446). Although many initial drainage procedures can be performed at the bedside for neuropathic patients, most require thorough debridement in the operating room. Anesthesia for such interventions may include local, region-

al, or general anesthetics. However, spinal blocks are typically avoided in patients who may be septic.

Even the sickest of patients should be considered for emergent incision, drainage, and debridement procedures, because their illness in this regard is directly attributable to the infection severity. Such life-threatening infections necessitate immediate surgical attention, without delay in obtaining radiologic or medical work-up of other comorbid conditions (41, 77, 462, 463). Polymicrobial infection should be anticipated in these patients (Fig 9), with a variety of gram positive cocci, gram negative rods, and anaerobic organisms predominating (287, 465, 466). Accordingly, empirical antibiotic therapy typically includes broad-spectrum coverage for more common isolates from each of these three categories (Table 11). Fully comprehensive empiric coverage is usually unnecessary unless the infection is life-threatening (118, 123).

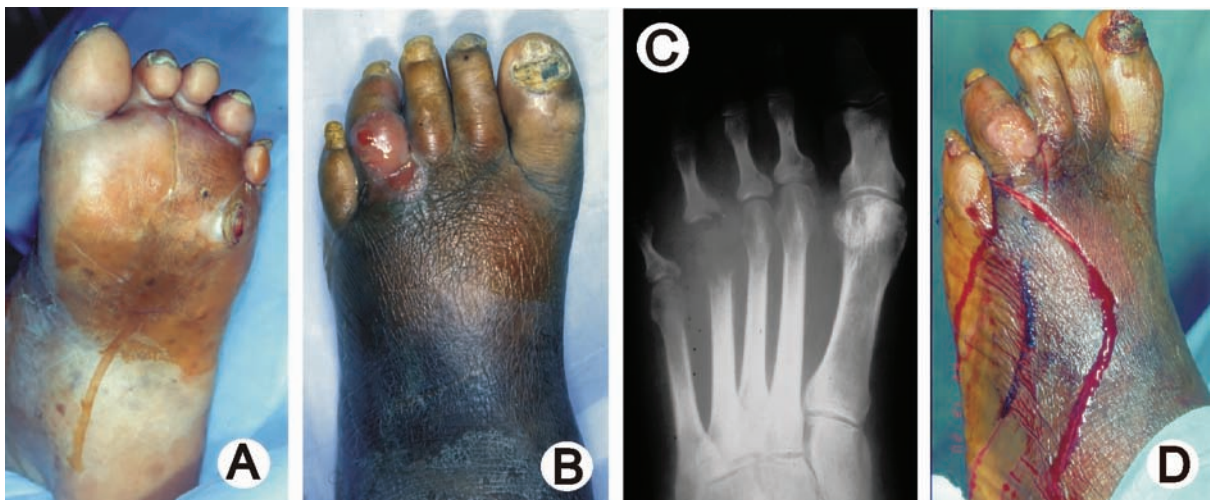Hospital therapies are usually initiated with intravenous medications, although most oral fluoroquinolones and oral linezolid have the same bioavailability as parenteral therapy (119, 438, 467). Once wound culture results become available, the initial antimicrobial therapy may require adjustment to provide more specific coverage or provide therapy against resistant organisms causing persisting infection. Recent evidence also supports the efficacy of initial parenteral therapy followed by the appropriate oral agent in the management of these patients (438, 466, 468). If the patient develops evidence of recurrent infection while receiving antibiotic therapy, repeat cultures should be

obtained to assess for superinfection. Methicillin-resistant staphylococci, which have emerged as important pathogens in chronically-treated diabetic foot ulcer patients (447, 448), must be detected early and treated appropriately to avoid further tissue loss or extension of infection.

The surgical wound may require repeated surgical debridement to completely eradicate infection and soft tissue necrosis (451, 460, 463). Wound care is initiated on day 1 or day 2 postsurgery and may initially involve saline gauze dressing changes. Other dressings may be used to aid in healing. Negative pressure wound therapy (V.A.C.<sup>®</sup>, KCI, San Antonio, TX) has been found particularly useful in this regard (393, 404, 410). If the wound fails to show signs of healing, the patient's vascularity, nutritional status, infection control, and wound off-loading must be re-evaluated.

Once soft tissue infection is under control and management of any osseous infection has been initiated, consideration may be given to wound closure or definitive amputation. Restoration and maintenance of function and independence is the ultimate goal for the patient (77, 463). The residual extremity requires close follow-up, regular diabetic foot exams, periodic foot care, and appropriate footwear therapy (25, 30, 151, 272).

Osteomyelitis and joint infection (Fig 11), when identified by clinical assessment or imaging studies, require a sampling of bone for microbiologic and histopathologic evaluation (200, 469). If the patient's soft tissue infection is controlled, consideration may be given to stopping antibiot-



**Figure 11** This 60-year-old female with diabetes and a history of plantar callus presented with (A) ulceration sub 4th metatarsal head and (B) 4th left toe, and poor diabetic control. A severe foot infection was apparent and (C) radiographs showed erosive disorganization of the 4th MTP joint. The patient developed a foot infection secondary to the plantar callus that progressed to osteomyelitis of the 4th toe and 4th metatarsal. (D) She was treated with parenteral antibiotics and ray resection.

ic therapy 24 to 48 hours presurgery to improve culture accuracy. A diagnosis of osteomyelitis requires that both culture and biopsy studies reveal positive findings, including necrosis, chronic inflammatory infiltrates, and positive isolation of bacteria (180). Resection of infected bone with or without local amputation and concurrent antimicrobial therapy is the most optimal management for osteomyelitis (124, 470). However, the routine need for surgery in this condition has recently been questioned (435). In some cases, based on patient morbidity or preferences, medical therapy alone for osteomyelitis might be warranted (123). If the affected bone has been completely resected or amputated, the infection may be treated as a soft tissue infection. However, if residual bone is present in the wound, the patient will likely require 4 to 8 weeks of antibiotic therapy based on the culture results (119, 287).

Intravenous or oral agents may be used, depending on the microbial isolates and infection severity (123). Antibiotic impregnated bone cement has been advocated for treatment of osteomyelitis, but it should only be used if the bone has been thoroughly debrided and the soft tissue envelope is adequate for wound closure following antibiotic-impregnated bead placement (471, 472). Gentamicin, tobramycin, or vancomycin are typically used in the beads. It is generally recommended that antibiotic beads be removed 2 weeks or so after placement. An alternative to bone cement is absorbable bone graft substitutes mixed with antibiotic powder (473). The pellets are gradually resorbed as the antibiotic is eluted, thus offering the advantage of avoiding a second operation for removal. While widely used in this regard, studies are lacking as to the efficacy of either modality compared with systemic antimicrobial therapy alone. If the infection fails to respond to therapy, the patient should be fully reassessed as previously discussed.

### **DIABETIC CHARCOT FOOT (NEUROPATHIC OSTEOARTHROPATHY) (Pathway 5)**

Charcot foot (neuropathic osteoarthropathy) is a progressive condition characterized by joint dislocation, pathologic fractures, and severe destruction of the pedal architecture. This condition can therefore result in debilitating deformity or even amputation (129, 131, 133-135, 474).

#### **Etiology of Neuropathic Osteoarthropathy**

The etiology of Charcot neuroarthropathy is most likely a combination of the effects involved in the neurovascular and neurotraumatic theories (79, 129, 130, 135, 138, 140, 475-477). Trauma superimposed on a severely neuropathic extremity is the most widely accepted theory regarding the

development of an acute Charcot foot (478). As a result of associated autonomic neuropathy, blood flow to the foot increases, resulting in osteopenia and attendant weakness of the bone (130, 139, 476, 479, 480). Because of the loss of protective sensation that accompanies peripheral sensory neuropathy, the patient is unaware of the initiating trauma and the profound osseous destruction that often occurs during ambulation. A vicious cycle ensues in which the patient continues to walk on the injured foot, allowing further damage to occur (129, 134, 478, 481) (Fig 12).

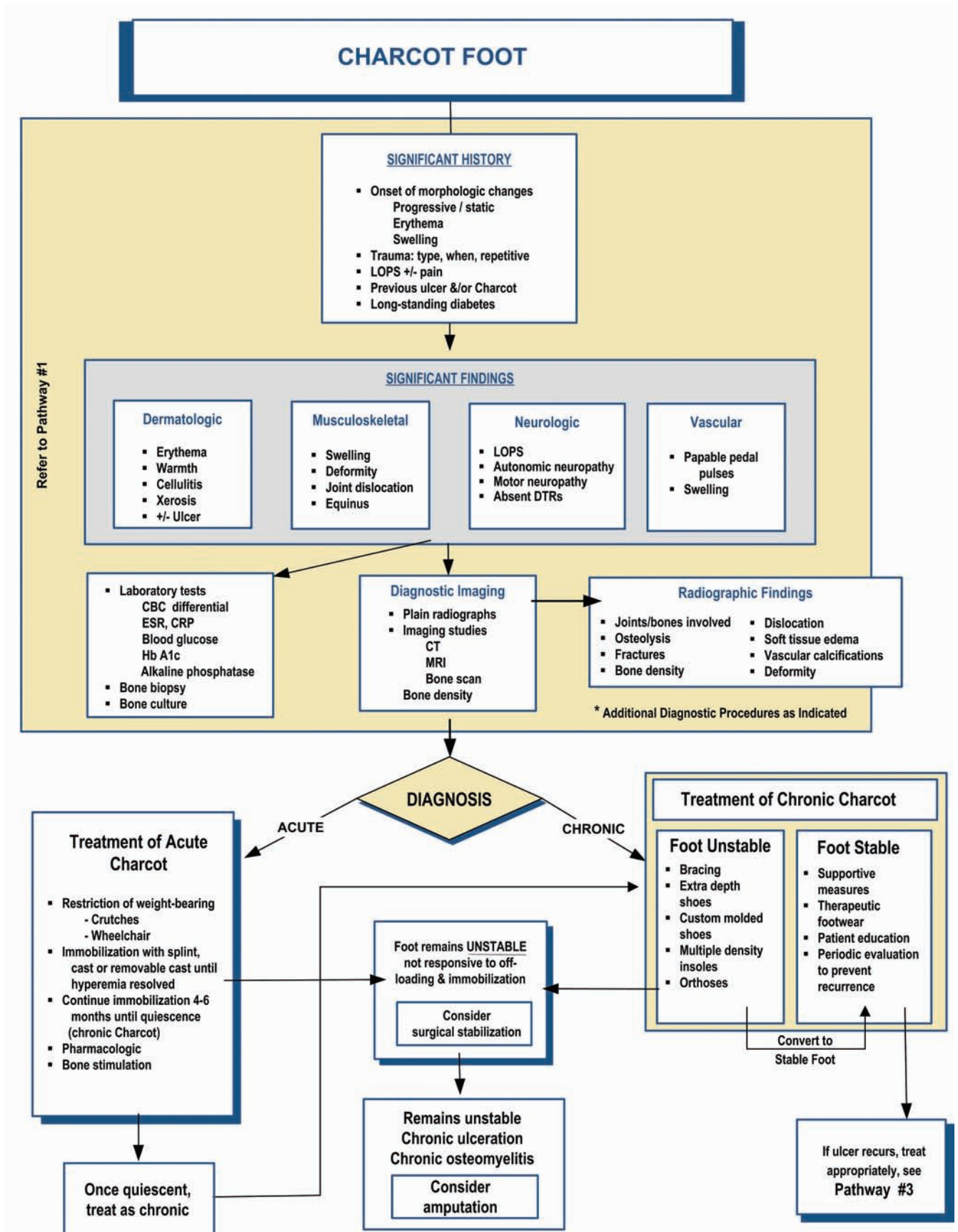
There is good evidence suggesting that the effects of neuropathy combined with associated vascular response are involved in the development of Charcot arthropathy (479, 482). Additionally, recent findings suggest that type 1 diabetes may have a greater preponderance of decreased bone density than type 2 diabetes (130, 483). Furthermore, the age of onset for acute Charcot arthropathy appears to be lower for type 1 than type 2 diabetes. Large cohorts of patients or patients with type 2 diabetes alone tend to be in their sixth to seventh decades at presentation, while patients with type 1 diabetes generally develop neuroarthropathy in the fourth to fifth decades (478, 483, 484). Various metabolic factors have also been implicated as potentially etiologic. One recent theory receiving much interest is the role of proinflammatory cytokines and the RANK-L - N-FkB pathway (485, 486). RANK-L, a member of the TNF- $\alpha$  superfamily, causes upregulation of the nuclear transcription factor  $\kappa$ B (NF- $\kappa$ B), leading to an increase in osteoclastogenesis and subsequent osteolysis. A decoy receptor for RANK-L, osteoprotegerin (OPG), modulates the activity of RANK-L and NF- $\kappa$ B expression. The excessive inflammation characteristic of the acute Charcot event likely disturbs the normal RANK-L/OPG balance and promotes the excessive osteolysis seen in this disorder. Vascular calcification, which is common in these patients, is also linked to this pathway (479, 487, 488).

#### **Clinical Diagnosis of Acute Charcot Arthropathy**

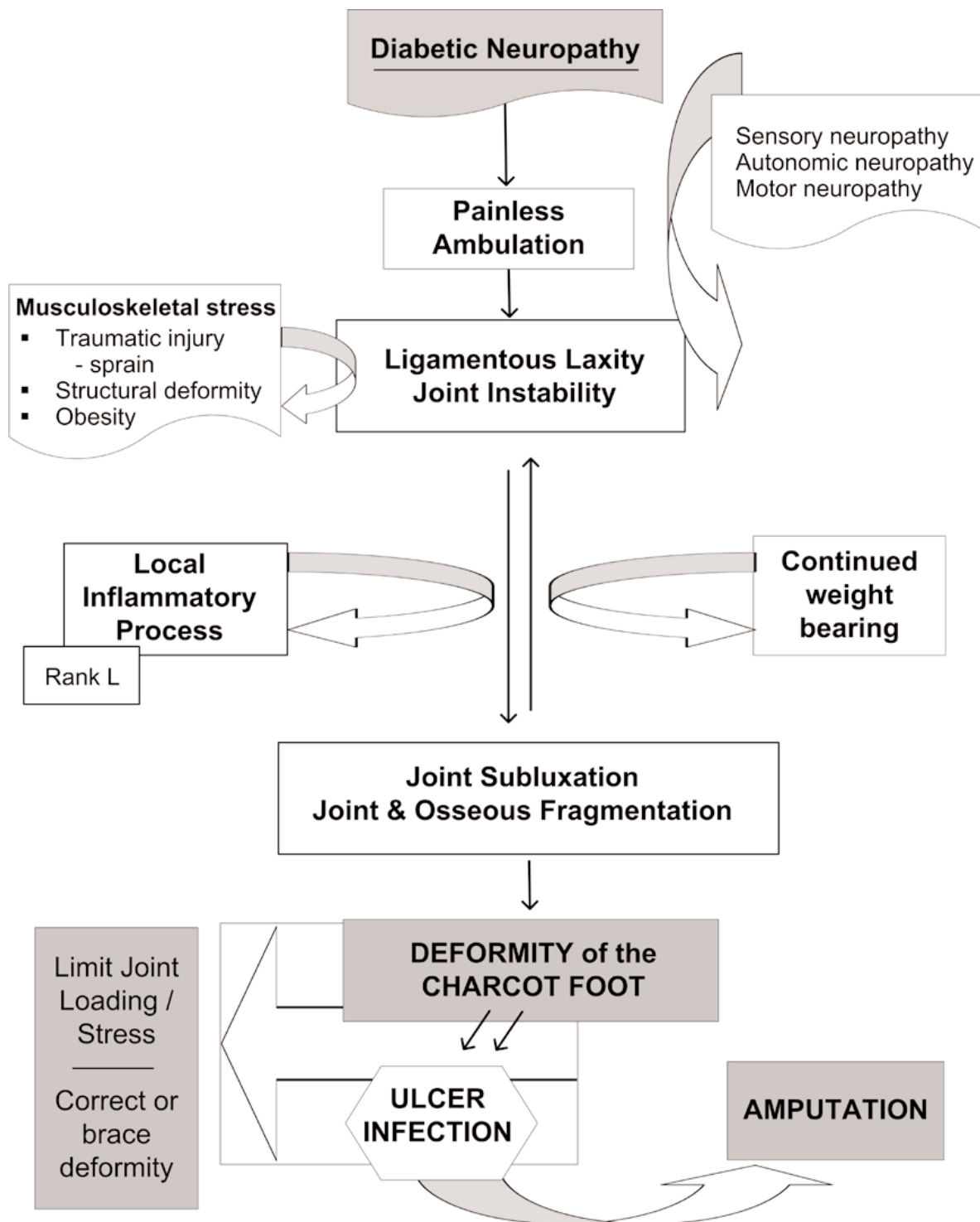
The initial diagnosis of acute Charcot arthropathy is often clinical, based on profound unilateral swelling, increased skin temperature, erythema, joint effusion, and bone resorption in an insensate foot (136, 478, 489, 490). These characteristics in the presence of intact skin are often pathognomonic of acute neuroarthropathy. In more than 75% of cases, the patient will present with some degree of pain in an otherwise insensate extremity (135). The diagnosis is complicated by the fact that in some cases, patients first present with a concomitant ulceration, raising questions of potential contiguous osteomyelitis (140, 491, 492).



**PATHWAY #5**







**Figure 12** Diabetic neuroarthropathy, or Charcot foot, is believed to be a neurologically-mediated complication of diabetes, with the development modified by musculoskeletal stress. The result is osseous fragmentation and joint subluxation with often significant morphologic changes in the architecture of the foot. Complications of the Charcot foot include ulceration under areas of bony prominence and potential amputation often related to infection/osteomyelitis that develops adjacent to the area of ulceration.

If the patient presents with a warm, edematous, erythematous, insensate foot, plain radiographs are invaluable in ascertaining presence of osteoarthropathy (493, 494). In most cases, no further imaging studies are required to make the correct diagnosis. With a concomitant wound, it may be difficult to differentiate acute Charcot arthropathy from osteomyelitis using plain radiographs alone (133, 183). Additional laboratory studies may prove useful in arriving at a correct diagnosis. The white blood cell count (WBC) with a left shift will often be elevated in acute osteomyelitis, although this can be blunted in diabetic patients (453). While the erythrocyte sedimentation rate and C-reactive protein level may also be elevated in acute infection, they often respond similarly to any inflammatory process and are therefore nonspecific. Bone biopsy, when indicated, is the most specific method for distinguishing osteomyelitis from osteoarthropathy in these circumstances. A biopsy consisting of multiple shards of bone and soft tissue embedded in the deep layers of synovium is pathognomonic for neuroarthropathy (495).

Technetium bone scans are generally nonspecific in assisting in the differentiation between osteomyelitis and acute Charcot arthropathy (179, 185). Indium scanning, while more expensive, has been shown to be more specific (179, 193, 496). Additional studies to aid in differentiating osteoarthropathy from osteomyelitis include bone scans utilizing Tc HMPAO-labeled white blood cells, MRI, and PET scanning (183, 186, 190, 207).

Other serologic markers can be helpful for the diagnosis of acute Charcot osteoarthropathy. A marker for increased osteoclastic activity, ICPT (carboxyterminal telopeptide of type 1 collagen), has been shown to be elevated but occurs without increased levels of procollagen carboxyterminal propeptide (PICP), a marker for osteoblastic activity (497-499). Nonetheless, the most important diagnostic aid in this situation remains a high index of clinical suspicion when a neuropathic patient presents with a swollen or deformed foot (478, 493, 494).

### **Classification of Charcot Arthropathy**

The most common classification system of Charcot arthropathy—the Eichenholtz classification system—is based on radiographic appearance as well as physiologic stages of the process. It divides the condition into three stages: developmental, coalescent, and reconstructive (495). The developmental stage is characterized by significant soft tissue swelling, osteochondral fragmentation, or joint dislocation of varying degrees. The coalescent stage is marked by a reduction in soft tissue swelling, bone callus proliferation, and consolidation of fractures. The recon-

structive stage is denoted by bony ankylosis and hypertrophic proliferation.

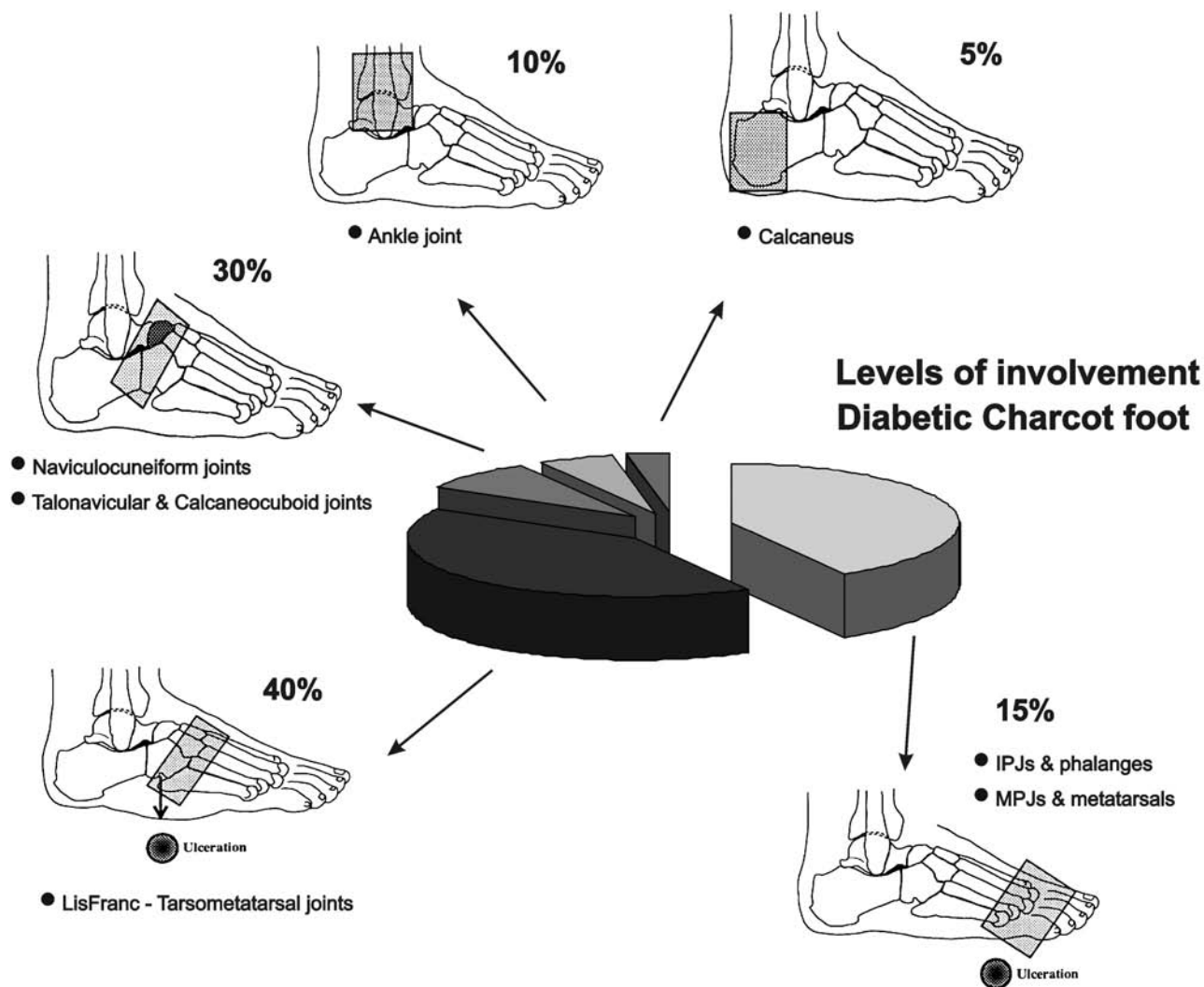
Radiologically, the Eichenholtz system is very descriptive and useful, but its practical applicability has limitations. In clinical practice, the initial stage is considered active, while the coalescent and reconstructive stages are considered quiescent or reparative. More recently, several authors have proposed an earlier stage 0 that corresponds to the initial inflammatory period following injury but prior to the development of characteristic bony radiographic changes (500-503). This prodromal period might be considered a “Charcot *in situ*” stage. Diagnosis of the condition during this period, in which no deformity has yet developed, could ostensibly arrest further progression of the destructive inflammatory process (494).

Another popular classification system is based on five anatomic sites of involvement but does not describe disease activity (129, 136) (Fig 13). Several other classification schemes are described in the literature, but none has been found to be superior or predictive of outcome (500, 504-506).

### **Management of Acute Charcot Neuroarthropathy**

Immobilization and stress reduction are the mainstays of treatment for acute Charcot arthropathy (129, 131, 135, 136, 478, 507, 508). Many clinicians advocate complete non-weightbearing through the use of crutches or other assistive modalities during the initial acute period. While this is an accepted form of treatment, three-point gait may in fact increase pressure to the contralateral limb, thereby predisposing it to repetitive stress and ulceration or neuropathic fracture (509). A short leg plaster or fiberglass non-weightbearing cast can additionally be used for acute Charcot events, even in patients with noninfected ulcerations (129, 135, 481). A soft compressive dressing in concert with a removable cast walker or pneumatic walking brace can also be used effectively in this regard (136, 139). Some centers prefer to initially apply a weightbearing total contact cast in the management of acute osteoarthropathy (135, 140, 493, 510-512). These ambulatory total contact casts should be changed at least every 1 to 2 weeks to adjust to limb volume changes as the edema decreases.

Following the initial period of off-loading, reductions in skin temperature and edema indicate the stage of quiescence, at which point the patient progresses into the postacute phase of treatment. Progression to protected weightbearing is permitted, usually with the aid of an assistive device. Through the use of appropriately applied total contact casts or other off-loading modalities (eg, fixed ankle walker, bivalved casts, total contact prosthetic walkers,



**Figure 13** Diabetic neuroarthropathy may be classified according to the anatomic location of joint involvement. The relative percentage of frequency of involvement is given. (Adapted from Sanders LJ and Frykberg RG. *The High Risk Foot in Diabetes Mellitus*, p108, Churchill Livingstone, New York, 1991)

patellar tendon-bearing braces), most patients may safely ambulate while bony consolidation of fractures progresses (129, 135, 477, 478). Charcot restraint orthotic walkers (CROW) or other similar total contact prosthetic walkers have gained acceptance as useful protective modalities for the initial period of weightbearing (513-515). A more readily available option is a pneumatic walking brace or similar removable cast walker that might incorporate a cushioned foot bed or insole. These “instant total contact casts” are made nonremovable by simply applying tape or a fiberglass cast roll around the body of the walker to help encourage compliance (50, 516).

The mean time of rest and immobilization (casting followed by removable cast walker) prior to return to permanent footwear is approximately 4 to 6 months (133-135, 474, 478, 493). Custom full-length inserts and comfort or

extra-depth shoes should be worn when protective bracing is no longer required (136, 138, 513). Moderately unstable ankles will benefit from an ankle foot orthosis (AFO) and high-top therapeutic shoe, while a severely unstable or maligned rearfoot will require a patellar tendon-bearing (PTB) brace incorporated into a custom shoe (493, 517, 518). The PTB brace has reportedly decreased mean rear-foot peak forces by at least 32% (517).

There is recent interest in the adjunctive use of bisphosphonate therapy in acute Charcot arthropathy to help expedite conversion of the acute process to the quiescent, reparative stage (519-521). These pyrophosphate analogs are potent inhibitors of osteoclastic bone resorption and are widely used in the treatment of osteoporosis, Paget’s disease, and reflex sympathetic dystrophy syndrome (50, 130). One randomized trial in the UK compared the use of a sin-

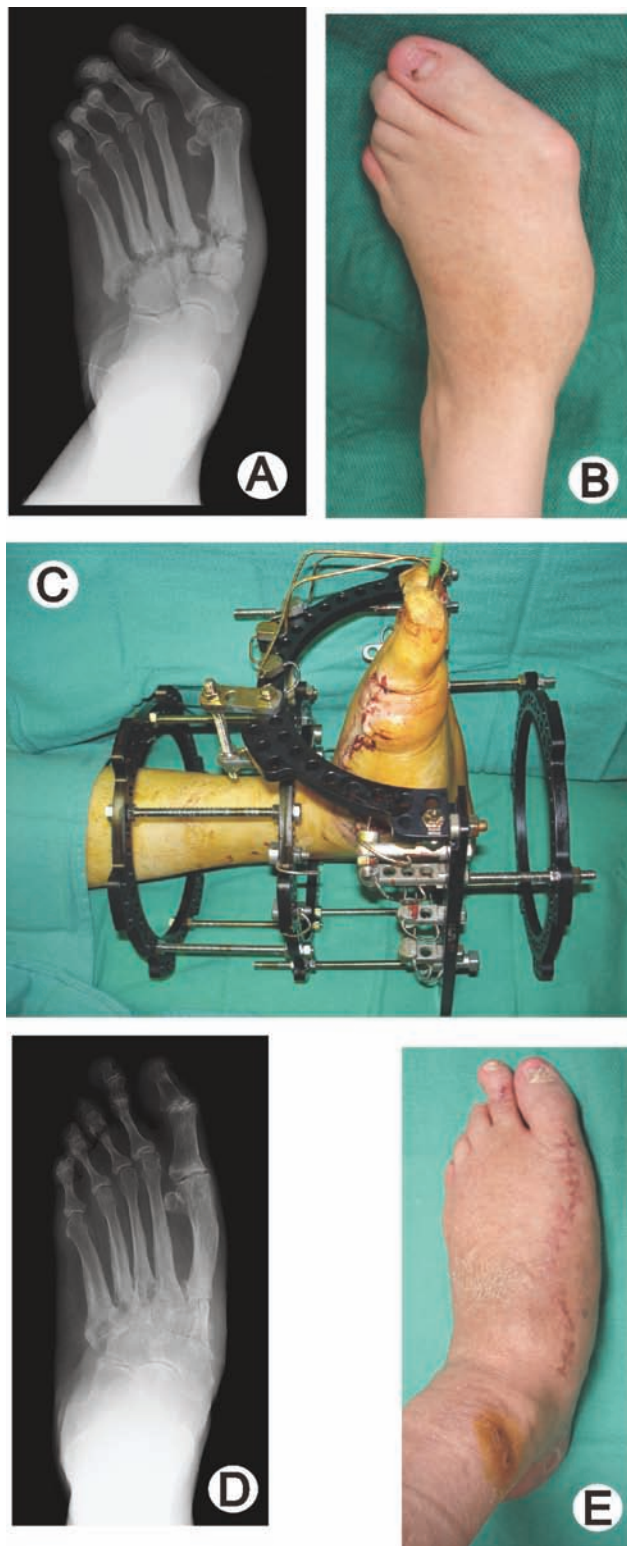
gle intravenous infusion of pamidronate with the use of saline infusion (498). The treatment group had significant declines in temperature and bone turnover markers (deoxypyridinoline crosslinks and bone specific alkaline phosphatase) in subsequent weeks compared with the control group, but no differences in clinical or radiographic outcomes were reported. A small trial comparing 6 months of oral alendronate plus off-loading with standard off-loading alone in acute Charcot patients found that the study group had significant reductions in 1CTP and hydroxyprolin, both of which are markers of bone resorption and increased foot bone density (499); no differences in clinical outcomes were noted.

Similarly, electrical bone growth stimulation has been applied to the management of acute neuroarthropathy to promote rapid consolidation of fractures (522-524). Low-intensity pulsed ultrasound (LIPUS) has also been suggested as a useful adjunct in promoting healing of Charcot fractures (525). Although promising in theory, none of these adjunctive treatments have yet been conclusively proven effective through large prospective multicenter, randomized trials.

### Surgical Management of Charcot Osteoarthropathy

Reconstructive surgery in acute Charcot may be considered if a deformity or instability exists that cannot effectively be controlled or accommodated by immobilization and off-loading (136, 140, 478, 500, 510, 511, 526). If the neuroarthropathy is identified in its early stages and non-weightbearing is instituted, surgery is usually unnecessary. According to consensus opinion, surgery in the acute stage is generally nonadvisable due to the extreme hyperemia, osteopenia, and edema present (131, 132, 134, 135, 477, 511, 527, 528). However, surgical intervention during the acute phase may be considered in the presence of acute subluxation without osteochondral fragmentation (509, 529). One small series reported successful arthrodeses rates with preserved foot function in patients with acute arthropathy of the midfoot (530). Nevertheless, this aggressive surgical approach needs confirmation through larger comparative trials prior to its adoption in the routine management of the acute Charcot foot.

As few as 4% to as many as 51% of patients presenting to tertiary centers are reported to undergo surgical procedures for Charcot deformities (474, 527, 528). However, such centers often receive chronic cases from multiple referral



**Figure 14** Severe midfoot collapse due to Charcot neuroarthropathy as shown (A) on radiograph and (B) in clinical presentation. (C) This patient was treated with tarsometatarsal arthrodesis using a multiplanar circular external fixator. (D) A postoperative radiograph and (E) clinical photograph at 4 months postoperative are shown here.

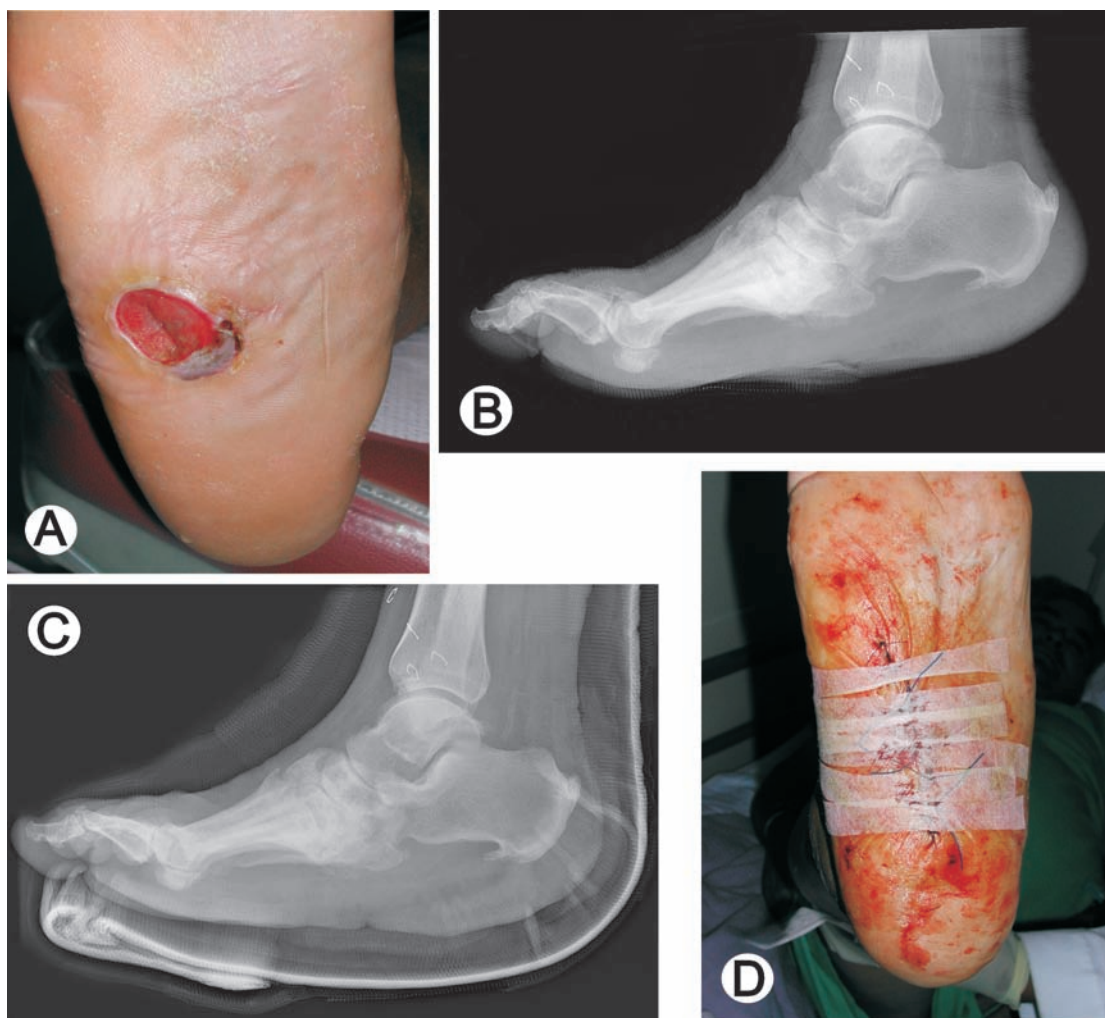


sources and with various degrees of deformity present; therefore, their rate of operation on these patients does not reflect the true incidence or need for such treatment in the community. A recent review of one center's experience with midfoot neuroarthropathy in 198 patients (201 feet) indicated that more than half of these patients could be successfully managed without surgery (510). Hence, large population-based studies are needed to assess the need for surgical intervention and compare the efficacy of various conservative therapies (474, 493, 520).

The goal of any surgery on the acute or chronic Charcot foot is to create a stable, plantigrade foot that may be appropriately accommodated (140, 478, 510, 530, 531). Most

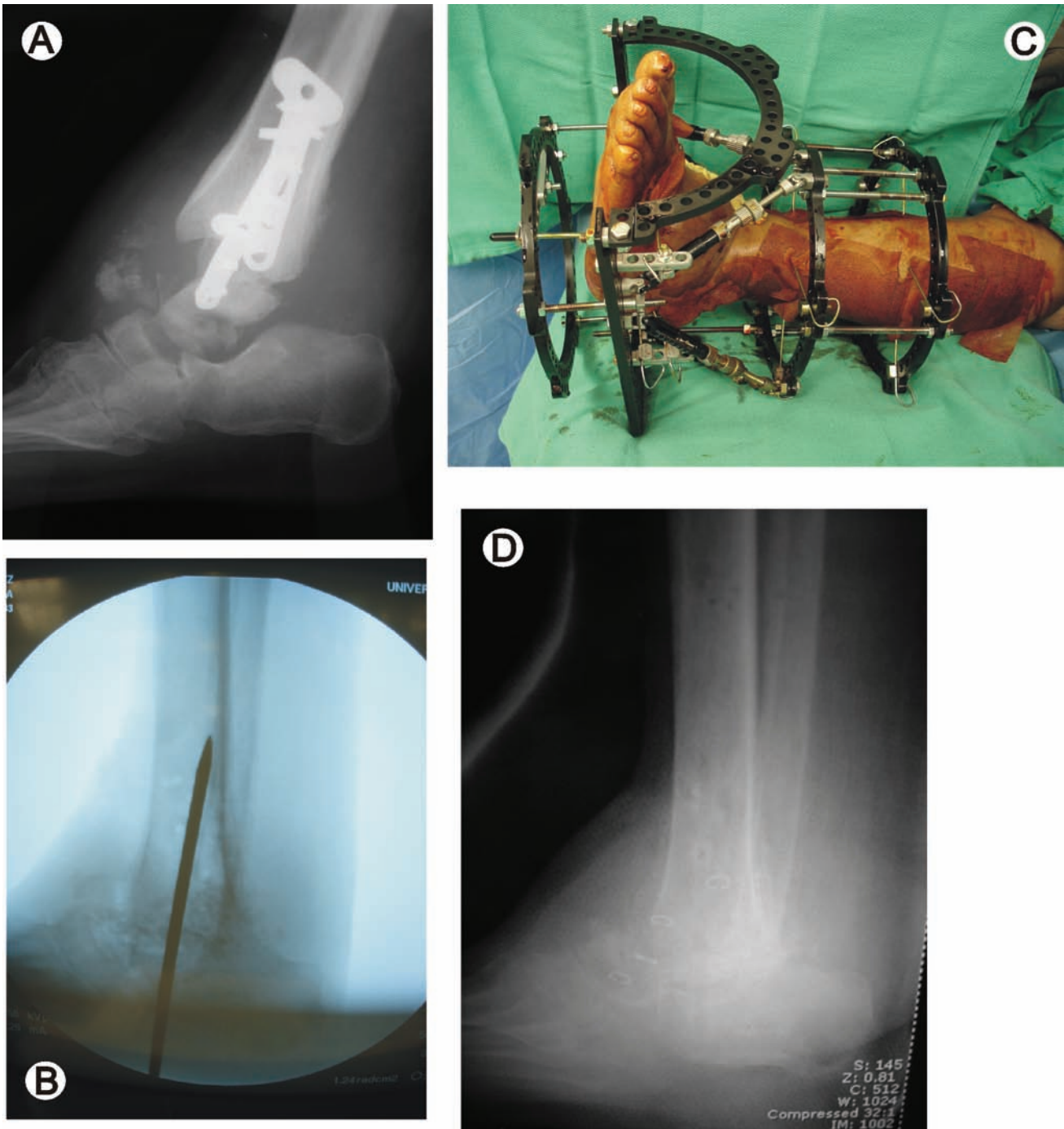
operations on chronic Charcot feet consist of exostectomies for prominent plantar ("rocker-bottom") deformities causing ulceration when the remainder of the foot is stable (135, 505, 511, 532) (Fig 14). However, more complex arthrodesis procedures are performed with increasing frequency and success, often using circular external fixation or intramedullary nails (140, 478, 526, 531, 533-537). These include isolated or multiple midfoot (Fig 15) or hindfoot fusions, triple arthrodeses, tibiocalcaneal fusions (Fig 16), and ankle fusions (538-542).

Following surgery, patients are immobilized until skin temperatures and postoperative edema normalize. As with patients treated nonsurgically, after prolonged cast immobi-



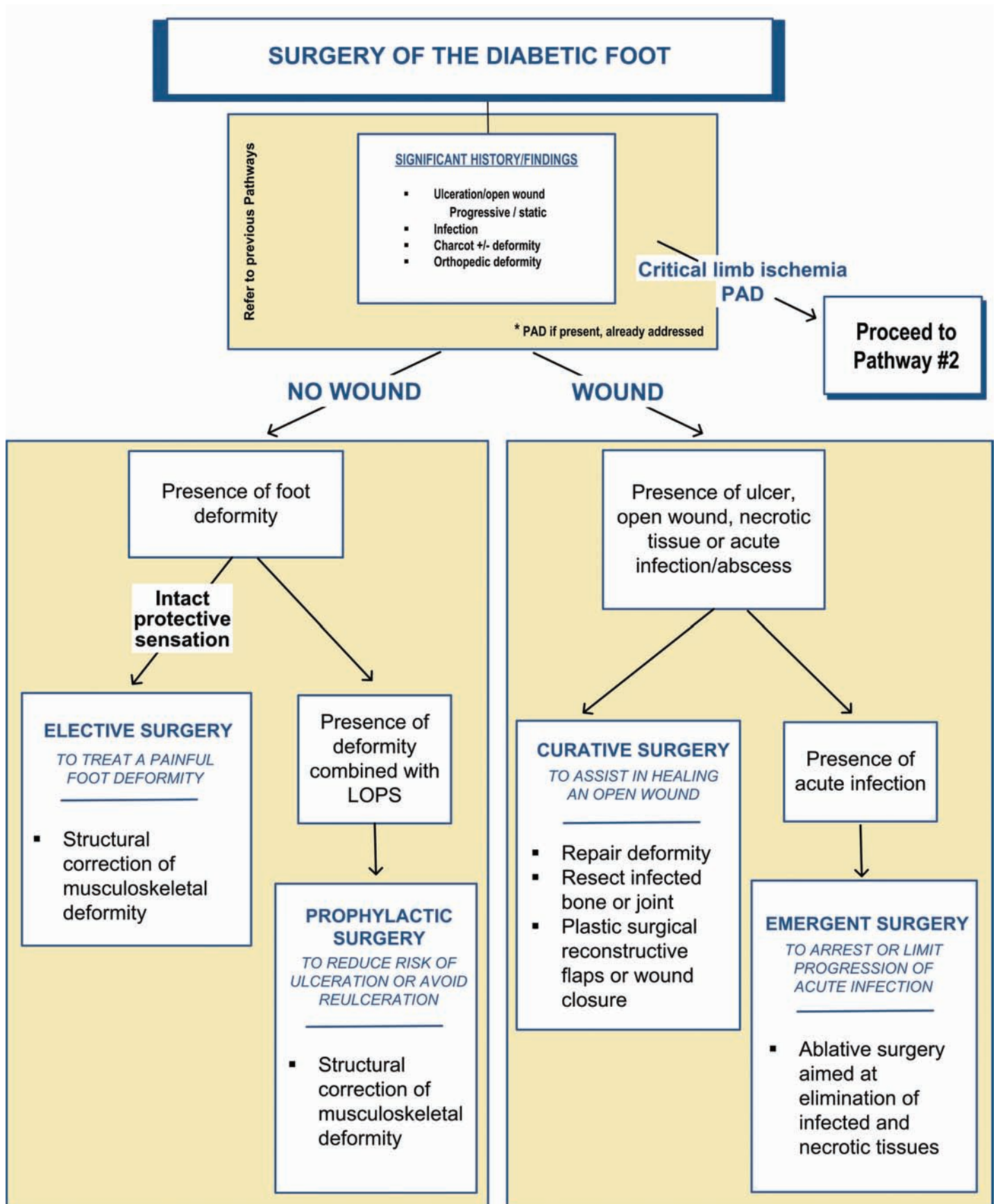
**Figure 15** (A) This Charcot patient presented with a recalcitrant ulceration below an area of bony prominence, (B) as shown on radiograph. Surgical management consisted of excision of the ulcer, (C) exostectomy, and (D) primary wound closure.





**Figure 16** This neuropathic diabetic patient sustained an ankle fracture and underwent open reduction internal fixation. (A) At 3 months postoperatively, radiographs revealed Charcot disorganization and loss of reduction. (B) The patient was brought back to surgery for talectomy and tibiocalcaneal fusion, shown in this intraoperative image. (C) A multiplanar circular external fixator was applied to accomplish the arthrodesis procedure. (D) Radiograph shows union at the arthrodesis site at 5 months postoperative.

**PATHWAY #6**



lization patients transition to a removable cast walker, followed by permanent prescription footwear or bracing (135, 543). Mean time from surgery to therapeutic shoes has been reported to be about 27 weeks (7 months) (135, 140, 530). Careful patient selection and management is the rule with these complex diabetic cases, since amputation can be a complication of failed surgical procedures (138, 474, 511, 527, 528, 533).

### **SURGICAL MANAGEMENT OF THE DIABETIC FOOT (Pathway 6)**

Surgical management of the diabetic lower extremity can be a daunting task, but with appropriate patient and procedural selection, successful resolution of ulceration and correction of inciting pathology may be achieved (270). Diabetic foot surgery performed in the absence of critical limb ischemia is based on three fundamental variables: presence or absence of neuropathy (LOPS), presence or absence of an open wound, and presence or absence of acute limb-threatening infection (270).

#### **Classifications of Surgery**

Surgical intervention has previously been classified as curative, ablative, or elective (100, 271). More recently, a modification of this scheme has been proposed that encompasses more procedures and a broader spectrum of patients (270), as follows:

Class I: *Elective* foot surgery (performed to treat a painful deformity in a patient without loss of protective sensation)

Class II: *Prophylactic* foot surgery (performed to reduce risk of ulceration or re-ulceration in patients with loss of protective sensation but without open wound)

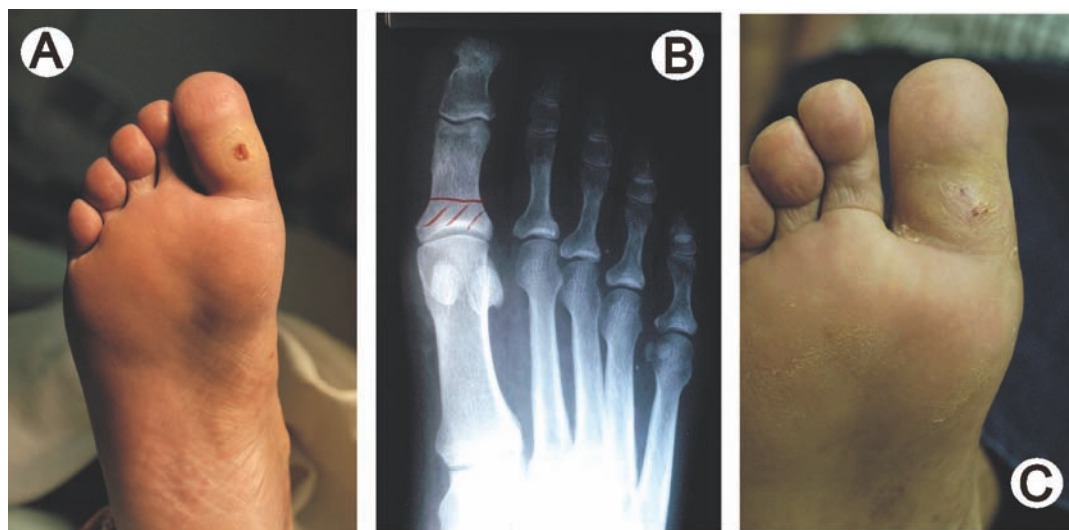
Class III : *Curative* foot surgery (performed to assist in healing an open wound)

Class IV: *Emergent* foot surgery (performed to arrest or limit progression of acute infection).

For any of these classes, the presence of critical ischemia should prompt a vascular surgical evaluation to consider the urgency of the procedure and possible revascularization prior to or subsequent to the procedure.

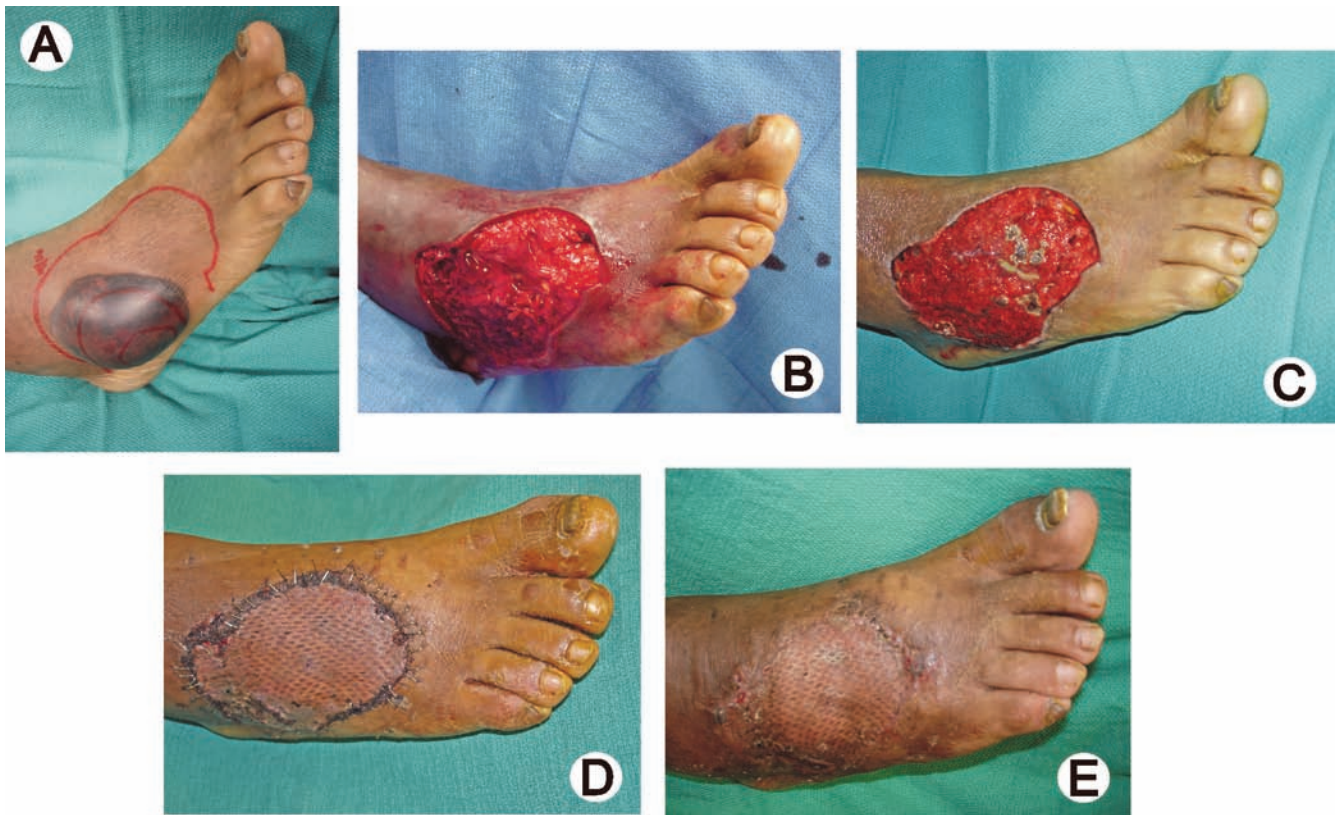
**Elective Surgery.** The goal of elective surgery is to relieve the pain associated with particular deformities such as hammertoes, bunions, and bone spurs in patients without peripheral sensory neuropathy and at low risk for ulceration. Essentially any type of reconstructive foot operation can fall into this category, including rearfoot and ankle arthrodeses as well as Achilles tendon lengthenings (544). However, amputations are generally not performed as elective procedures, except in cases of severe deformity or instability resulting from prior injury or neuromuscular diseases.

**Prophylactic Surgery.** Prophylactic procedures are indicated to prevent ulceration from occurring or recurring in patients with neuropathy, including those with a past history of ulceration (but without active ulceration). These pro-



**Figure 17** This patient has a (A) hallux ulceration related to the loss of normal joint mobility that is often seen in diabetes. During weightbearing, this clinical hallux limitus/rigidus places untoward pressure at the interphalangeal joint. (B) Radiograph illustrates planned resection arthroplasty of the 1st MTP joint. (C) The ulcer subsequently healed during the immediate postoperative period.





**Figure 18** This diabetic patient presented with (A) a bullous abscess with peripheral cellulitis. Initial treatment included debridement, revealing (B) extensive necrosis. Local wound care allowed for (C) development of a healthy granulating wound base, followed by application of a split-thickness skin graft. (D) Foot at 3 weeks postoperative and (E) later at 7 weeks shows healing of this potential limb-threatening infection.

cedures involve correcting an underlying tendon, bone, or joint deformity. Many reconstructive procedures in this category would be considered elective if the patient did not have sensory neuropathy and a higher risk for ulceration (270).

**Curative Surgery.** Curative procedures are performed to effect healing of a nonhealing ulcer or a chronically recurring ulcer when off-loading and standard wound care techniques are not effective (100, 271). These include multiple surgical procedures aimed at removing areas of chronically increased peak pressure as well as procedures for resecting infected bone or joints as an alternative to partial foot amputation (30, 54, 77, 173). Operations frequently performed in this regard include exostectomy, digital arthroplasty, sesamoidectomy, single or multiple metatarsal head resection, joint resection (Fig 17), or partial calcaneotomy (272, 273, 545-557). Some surgeons have proposed the advantages of combining plastic surgical flaps and skin grafts with these procedures to expedite wound healing and provide for more durable soft tissue coverage (54, 173, 558-563).

**Emergent Surgery.** Emergent procedures are performed to stop the progression of infection. Such ablative surgical intervention, most often involving amputation, requires removal of all infected and necrotic tissue to the level of viable soft tissue and bone (Fig 18). When possible, they are also performed in a manner to allow for the maximum function from the remaining portion of the limb (77, 272).

Wounds may be closed primarily if the surgeon is confident no infection or ischemic tissue remains and if enough soft tissue is available. Other wounds may initially be packed open, requiring well controlled and frequently assessed wound care, with delayed primary closure or closure by secondary intention. Another popular option is negative pressure wound therapy using a V.A.C.<sup>®</sup> device, which has been found to significantly expedite granulation tissue formation and healing of open partial-foot amputations (410). Mechanical assistance using a variety of skin-stretching devices are the surgeon's option and may help attain delayed primary closure for some wounds (564, 565). More often, V.A.C.<sup>®</sup> therapy is used to manage large or



deeper wounds until delayed primary closure can be achieved (393, 404, 566). Other approaches include plastic surgical techniques utilizing split and full-thickness skin grafts and a variety of flaps (173, 558, 559, 562, 563).

Each patient must be assessed for the selection of the surgical management that best meets his or her needs. Secondary wound healing with or without adjunctive wound therapies may still be the best choice for some patients. Pathway 6 lists the various types of surgical procedures commonly used for managing diabetic foot complications.

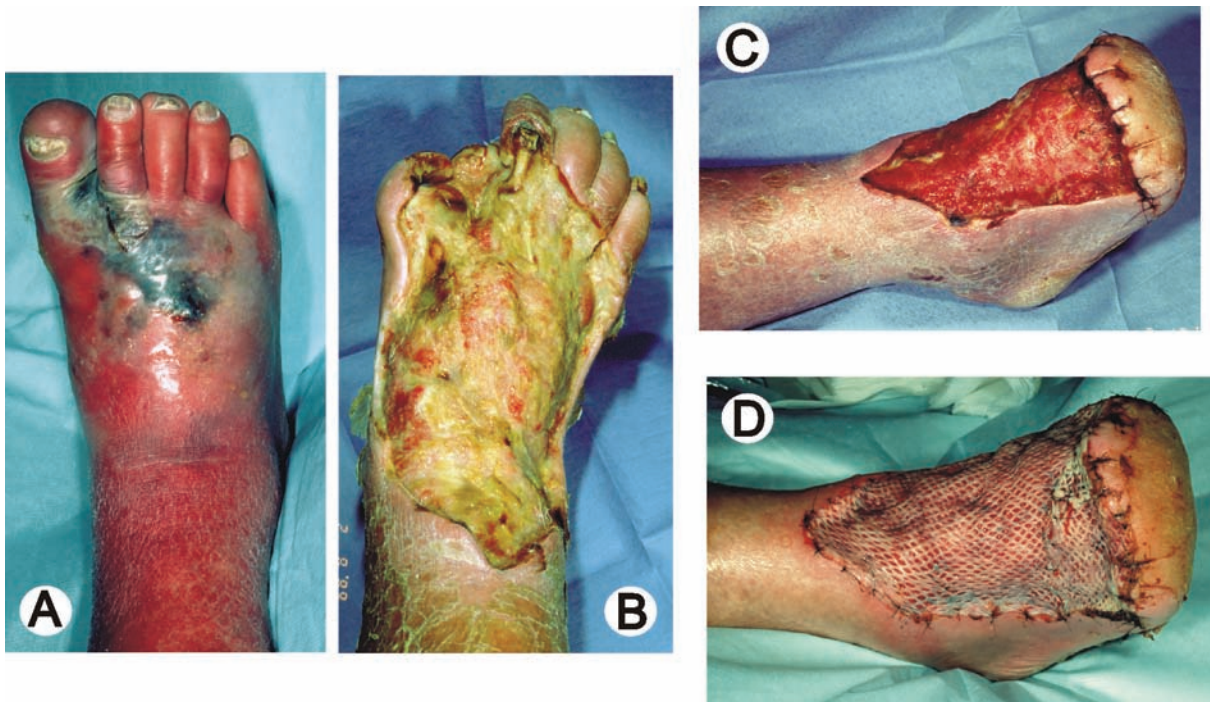
In the carefully selected patient, prophylactic or elective surgical correction of structural deformities that cannot be accommodated by therapeutic footwear can serve to reduce high pressure areas and ultimately prevent ulcer recurrence (255, 270, 271, 273, 545, 547, 548, 550, 567-569). Many of the procedures mentioned in the discussion on curative surgery would also be indicated in the elective/prophylactic

reconstruction of the nonulcerated foot. Common operations performed in this regard include the correction of hammertoes, bunions, and various exostoses of the foot. Tendo-achilles lengthening procedures are often performed as ancillary procedures to reduce forefoot pressures that contribute to recurrent ulcerations (55, 58, 61, 568, 570).

Once healed, these surgical patients are at high risk for future ulceration and require appropriate ongoing care consistent with those prevention strategies already discussed (30, 163, 173, 253, 255, 256, 571).

### Amputation Considerations

Amputation, a well recognized consequence in the management of the diabetic foot, is performed for a variety of reasons and can be characterized as curative or emergent. Indications for amputation include removal of gangrenous or infected tissue, often to control or arrest the spread of infection; removal of portions of the foot that frequently



**Figure 19** (A) This 65-year-old male presented with a severe limb-threatening infection with deep necrosis of the forefoot. (B) He underwent incision and drainage with wound debridement including tendons on the dorsum of the foot and hallux amputation. (C) This was later converted to a transmetatarsal amputation with continuing dorsal wound care. (D) Good granular response allowed for later placement of a split-thickness skin graft.

## Amputation Prevention Program



1. Podiatric Foot Care
  - Regular visits, examinations, and footcare
  - Risk assessment
  - Early detection and treatment of new lesions
2. Protective Shoes
  - Adequate room to protect from injury
  - Well cushioned walking sneakers
  - Extra depth or custom-molded shoes
  - Shoe modifications as needed
3. Pressure Reduction
  - Cushioned multiple density insoles
  - Custom orthotic devices or braces
  - Padded hosiery
  - Pressure measurements - computerized or pressure sensitive mat
4. Prophylactic Surgery
  - Correct structural deformity: hammertoes, bunion, exostoses
  - Prevent recurrent ulcers over deformities
5. Preventive Education
  - Patient education - need for daily inspection & necessity for early intervention
  - Physician education - significance of foot lesions, importance of regular foot examinations, & current concepts of diabetic foot management

**Figure 20** An effective amputation prevention program includes regular podiatric foot care, protective shoes, and pressure reduction as well as prophylactic foot surgery combined with both patient and physician education programs.

ulcerate; and creation of a functional unit that can accommodate either normal or modified shoe gear.

In general, the amputation should be performed at a level that balances preservation of limb length and function with the capacity for the surgical site to heal primarily (572-575). Although this concept is intuitive, several factors may influence the selection of the level of amputation. It is well recognized that energy expenditure increases as the level of amputation becomes more proximal (576, 577). Simple tasks such as ambulating to the bathroom or other activities of daily living become increasingly more difficult for the patient commensurate with the level of amputation. In addition, patients with more proximal amputations are far more difficult to rehabilitate to a functional community or household ambulation level.

Recent advances in vascular surgery have enabled the level of amputation to become more distal or “limb sparing” (77, 166, 173). The capacity to re-establish distal perfusion

with endovascular techniques or bypass surgery to the distal tibial, peroneal, and pedal arteries has greatly enhanced the potential for more distal amputation (306, 307). In most circumstances, patients should be given the opportunity for vascular surgical intervention prior to definitive amputation so that the most distal level of amputation can be successful.

### Goals of Selection of Amputation Level

The selection of the level of amputation should incorporate the following goals:

- Creation of a distal stump that can be easily accommodated by a shoe insert, orthotic device, modified shoe gear, or prosthesis
- Creation of a distal stump that is durable and unlikely to break down from exogenous pressure

- Creation of a distal stump that will not cause muscle or other dynamic imbalances. Examples include medial migration of the lesser digits after 1st MTP joint disarticulation; varus deformity and lateral overload after 5th ray resection; and equinus contracture after transmetatarsal or Chopart amputation.
- Healing with primary intention. In most instances it is advisable to perform an amputation at the most distal level that would allow for primary healing. Unfortunately, there are few objective tests or strategies that can consistently and reliably predict healing potential.

The cost of failure of an amputation at a given level is multifaceted. Increased costs associated with a more proximal level of amputation involve hospitalization, surgical procedures, prostheses, and psychological effects on the patient. It is difficult to stratify the importance of each of these parameters; each should be given consideration before any amputation.

### Curative Versus Emergent Surgery

Although it is usually preferable to perform the amputation in an elective, controlled environment, this is not always possible or prudent. When infection, necrotizing fasciitis, or gas gangrene are present, an open amputation may need to be done on an emergent basis (150, 578) (Fig 19). Prior to the definitive amputation, residual infection and ischemia can be addressed. When performed under elective and stable conditions, the amputation should be fashioned so that it is curative. This generally means that the primary incision site can be closed primarily and that no further surgery is anticipated. With primary or even secondary wound healing, the patient can then be fitted for appropriate shoe gear or walking aids. When performed under emergent conditions, the procedure should usually be done proximal to the level of all necrotic tissue. It is anticipated that additional surgical procedures will be necessary to attain a closed wound and a stump that can accommodate shoes, custom inserts, or a prosthesis (575).

Amputation prevention strategies are identical to those employed for preventing ulceration and have previously been discussed (Fig 20). Prevention is best facilitated through a multidisciplinary approach that focuses not only

on the aggressive management of diabetic foot lesions or infections, but also on periodic screening of all diabetic patients, regular surveillance of high-risk persons, education on risk factors and daily foot care, and provision of therapeutic footwear for patients with a history of ulceration, ischemia, or structural deformities (163, 251, 255, 301).

### CONCLUSION

Ulceration, infection, gangrene, and lower extremity amputation are complications often encountered in patients with diabetes mellitus. These complications frequently result in extensive morbidity, repeated hospitalizations, and mortality. They take a tremendous toll on the patient's physical and mental well-being as well as impose a substantial economic burden, often removing the patient from the workforce and placing a financial drain on the health care system. According to a recent study, the mean annual cost of treating an uninfected ulcer was \$9,306, while the cost of treating an ulcer with osteomyelitis exceeded \$45,000 (579). Indeed, the estimated annual cost of treating diabetic peripheral neuropathy with its complications (including ulceration and amputation) ranges from \$1.5 and \$13 billion (40, 579).

Not all diabetic foot complications can be prevented, but it is possible to dramatically reduce their incidence through appropriate management and prevention programs. The multidisciplinary team approach to diabetic foot disorders has been demonstrated as the optimal method to achieve favorable rates of limb salvage in the high-risk diabetic patient (165, 166, 173, 253, 278, 300, 458, 459). Foot care programs emphasizing preventive management can reduce the incidence of foot ulceration through modification of self-care practices, appropriate evaluation of risk factors, and formulation of treatment protocols aimed at early intervention, limb preservation, and prevention of new lesions. The foot and ankle surgeon should play an integral role in this scheme, providing ongoing surveillance, education, and management of new or impending lesions (48, 255, 296). A significant reduction in both major and minor diabetic limb amputations is certainly attainable if clinicians embrace these principles and incorporate them into daily patient care.

# Appendix 1 p1

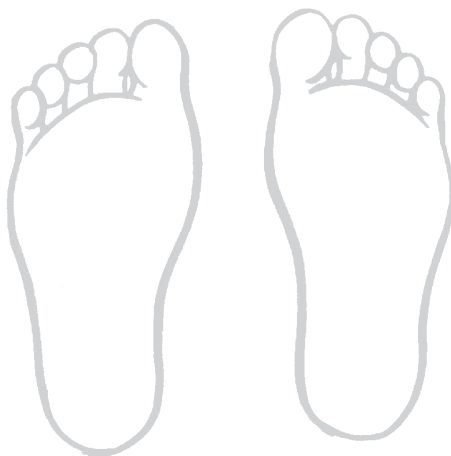
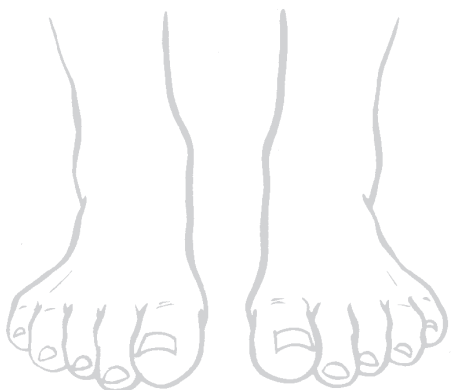
## Diabetic Foot Evaluation

Patient: \_\_\_\_\_

Chart # \_\_\_\_\_ Age: \_\_\_\_\_

Date: \_\_\_\_\_



/// Mark areas of callus, ulcer or pre-ulcer, erythema, swelling, tenderness or deformity

Medications:

- Type 1
- Type 2
- Rx - Insulin
  - Incretin
  - Oral Hypoglycemic
  - Diet

Diabetes duration \_\_\_\_\_

Attending MD \_\_\_\_\_

Height \_\_\_\_\_ Weight \_\_\_\_\_

BP \_\_\_\_\_ HbA1C \_\_\_\_\_

### History of:

- Foot Ulcer \_\_\_\_\_
- Infection \_\_\_\_\_
- Amputation \_\_\_\_\_
- Revascularization \_\_\_\_\_
- Renal Disease \_\_\_\_\_
- CAD \_\_\_\_\_
- Stroke \_\_\_\_\_
- Tobacco \_\_\_\_\_
- Alcohol \_\_\_\_\_

- Paresthesia/Tingling \_\_\_\_\_
- Numbness \_\_\_\_\_
- Burning \_\_\_\_\_
- Sharp Pain \_\_\_\_\_
- Night Pain \_\_\_\_\_
- Muscle Weakness \_\_\_\_\_
- Gait Difficulties \_\_\_\_\_
- Claudication \_\_\_\_\_

toes  
plantar  
feet to above ankle  
... to below knee  
night  
daily  
occasionally

wheelchair  
walker  
cane  
brace  
foot orthosis  
MDI

Shoes \_\_\_\_\_

### Skin:

- Turgor \_\_\_\_\_
- Color \_\_\_\_\_
- Temperature \_\_\_\_\_
- Texture \_\_\_\_\_

### Lesions

- Fissures \_\_\_\_\_
- Corns \_\_\_\_\_
- Calluses \_\_\_\_\_
- Ulcers \_\_\_\_\_
- Nails \_\_\_\_\_

### Musculoskeletal

- Joint Flexibility \_\_\_\_\_
- Deformities \_\_\_\_\_
- or Sites of \_\_\_\_\_
- High Pressure \_\_\_\_\_
- Gait assessment \_\_\_\_\_



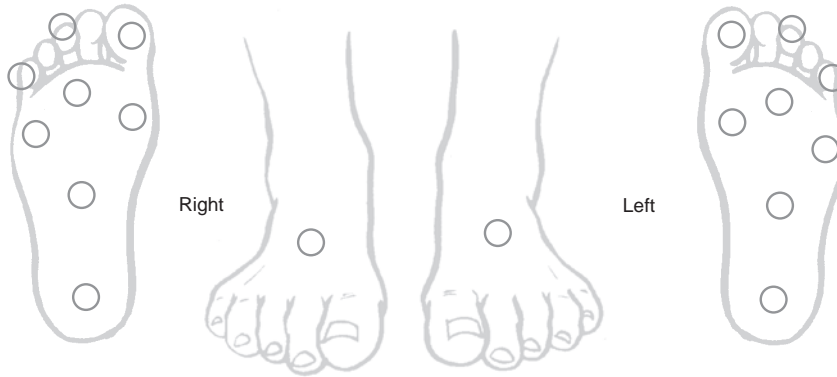
# Appendix 1 p2

## Neurologic Exam

**Sensory** - Semmes-Weinstein Monofilament  
 Ability to detect 5.07 or 10 gm Monofilament: + or -

## Deep Tendon Reflexes (+Present; - Absent)

	Right	Left
Patella	_____	_____
Achilles	_____	_____



## Vascular Exam

	Right				Left				Pulse Exam
Pulses:									0 absent
Dorsalis Pedis	0	+1	+2	+3	0	+1	+2	+3	+1 diminished
Posterior Tibial	0	+1	+2	+3	0	+1	+2	+3	+2 normal
									+3 bounding
Elevation Pallor	Absent Present				Absent Present				
Dependent Rubor	Absent Present				Absent Present				
Capillary Filling Time	<1	1-3	>3		<1	1-3	>3		
Edema	Absent				_____				

## Risk Status

- 0 No Sensory Neuropathy, No PAD, Negative Hx of Foot Ulcer
- I Neuropathy (LOPS), No PAD, No Deformity
- II Sensory Neuropathy + PAD &/or Foot Deformity
- III Previous Foot Ulcer or Amputation
  - Prior Ulceration &/or Amputation
  - Charcot Deformity - Location

## Recommended Management:

- Periodic Foot Care
- Extra Depth Shoes
- Multiple Density Insoles (MDI), Orthotics
- Bracing
- Vascular Testing: Doppler
- Consultation:
- Other: Diabetic Education

Examiner: \_\_\_\_\_

Date: \_\_\_\_\_

\_\_\_\_\_

\_\_\_\_\_

\_\_\_\_\_

\_\_\_\_\_

\_\_\_\_\_

## Appendix 2: Definitions

**Amputation:** The complete or partial removal of a limb or body appendage by surgical or traumatic means. A minor amputation is defined as occurring distal or through the tarsometatarsal joint (Forefoot, Transmetatarsal, and Lisfranc). Major amputations are those that occur proximal to the tarsometatarsal joint (Chopart, Boyd, Syme, Below Knee, and Above Knee).

**Charcot foot** (arthropathy, osteoarthropathy, neuroarthropathy): Non-infectious destruction of bone and joint that is associated with neuropathy.

**Diabetic foot:** Describes the foot of a diabetic patient that has the potential risk of pathologic consequences, including infection, ulceration, and destruction of deep tissues associated with neurologic abnormalities, various degrees of peripheral arterial disease, and metabolic complications of diabetes in the lower limb. (Based on the World Health Organization definition)

**Diabetes, type 1:** Formerly called insulin-dependent diabetes mellitus (IDDM), describes an autoimmune disease of younger individuals with a lack of insulin production that causes hyperglycemia and a tendency toward ketosis.

**Diabetes, type 2:** Formerly called non-insulin-dependent diabetes mellitus (NIDDM), describes a metabolic disorder resulting from the body's inability to produce enough insulin or properly utilize insulin. Individuals with type 2 diabetes also have hyperglycemia but are ketosis-resistant.

**Epidemiology:** The study of frequency, determinants, and distribution of disease.

**Gangrene:** The death or necrosis of a part of the body secondary to injury, infection, and/or lack of blood supply. This indicates irreversible damage where healing cannot be anticipated without loss of some part of the extremity.

**Incidence:** The rate at which new cases of disease occur within a specified time period.

**Infection:** An invasion and multiplication within body tissues by organisms such as bacteria, fungi, or yeast, with or without the clinical manifestation of disease.

**Intrinsic minus foot:** Describes a neuropathic foot with intrinsic muscle wasting and associated claw toe deformities.

**Ischemia:** The impairment of blood flow secondary to an obstruction or constriction of arterial inflow.

**LEAP:** Acronym for Lower Extremity Amputation Prevention program.

**Limited joint mobility:** Describes the stiffness or restricted range of motion of a joint (cheiroarthropathy) due to protein glycosylation.

**LOPS:** Acronym for loss of protective sensation. Describes the progression of neuropathy in the diabetic foot to the point that the foot is at risk for ulceration.

**Neuropathy.** A nerve dysfunction affecting sensory, motor, and/or autonomic fibers, with varying degrees of impairment, symptoms, and signs. **Diabetic peripheral neuropathy** is the presence of symptoms and/or signs of peripheral nerve dysfunction in individuals with diabetes after exclusion of other causes.

**Prevalence:** A measure of frequency describing the percent of persons in a given population with a stated disease or characteristic at a point in time.

**Ulceration (ulcer):** A partial- or full-thickness defect in the skin that may extend to subcuticular tissue, tendon, muscle, bone, or joint.

## References

1. Boulton AJ, Vileikyte L, Ragnarson-Tennvall G, Apelqvist J. The global burden of diabetic foot disease. *Lancet* 366:1719-1724,2005.
2. Singh N, Armstrong DG, Lipsky BA. Preventing foot ulcers in patients with diabetes. *JAMA* 293:217-228, 2005.
3. International Diabetes Federation and International Working Group on the Diabetic Foot . *Diabetes and Foot Care: Time to Act*, International Diabetes Federation, Brussels, 2005.
4. Wild S, Roglic G, Green A, Sicree R, King H. Global prevalence of diabetes: estimates for the year 2000 and projections for 2030. *Diabetes Care* 27:1047-1053, 2004.
5. Centers for Disease Control and Prevention. National diabetes fact sheet: general information and national estimates on diabetes in the United States, Centers for Disease Control and Prevention, Atlanta, 2005.
6. Centers for Disease Control and Prevention. *Diabetes: a serious health problem. At-a-Glance 2000*, Center for Disease Control and Prevention, 2000.
7. Centers for Disease Control and Prevention. *Diabetes: Disabling, Deadly, and on the Rise: At-a-Glance, 2005*, Centers for Disease Control and Prevention, Atlanta, 2005.
8. American Diabetes Association. *Diabetes 1996 Vital Statistics*, American Diabetes Association, Alexandria, VA, 1996.
9. Harris MI. Diabetes in America: epidemiology and scope of the problem. *Diabetes Care (Suppl)*3:C11-C14, 1998.
10. Centers for Disease Control and Prevention. *Data and Trends: National Diabetes Surveillance System, Vol. 2006*, National Center for Chronic Disease Prevention and Health Promotion, Atlanta, 2005.
11. American Diabetes Association. Report of the Expert Committee on the diagnosis and classification of diabetes mellitus. *Diabetes Care (Suppl.1)*:S4-S19, 2000.
12. American Diabetes Association. *Diabetes Facts and Figures, 2000*, American Diabetes Association, Alexandria, VA, 2000.
13. American Diabetes Association. Economic costs of diabetes in the U.S. in 2002. *Diabetes Care* 26:917-932, 2003.
14. Palumbo PJ, Melton LJ. Peripheral vascular disease and diabetes. In: *Diabetes In America*, pp 1-21, edited by Harris MI and Hamman RF, National Institutes of Health, Bethesda, 1985.
15. Reiber GE. Epidemiology of foot ulcers and amputations in the diabetic foot. In: *The Diabetic Foot*, pp 13-32, edited by JH Bowker and MA Pfeifer, Mosby, St. Louis, 2001.
16. Reiber GE, Boyko EJ, Smith DG. Lower extremity foot ulcers and amputations in diabetes. In: *Diabetes in America*, 2nd ed, pp 409-427 , edited by MI Harris, C Cowie, and MP Stern, NIH Publication No. 95-1468; 1995.
17. Frykberg RG, Habershaw GM, Chrzan JS. Epidemiology of the diabetic foot: ulcerations and amputations. In: *Contemporary Endocrinology: Clinical Management of Diabetic Neuropathy*, p 273, edited by A Veves, Humana Press, Totowa, NJ, 1998.
18. Moss SE, Klein R, Klein BEK. The prevalence and incidence of lower extremity amputation in a diabetic population. *Arch Intern Med* 152:610-616, 1992.
19. Ramsey SD, Newton K, Blough D, McCulloch DK, Sandhu N, Reiber GE, Wagner EH. Incidence, outcomes, and cost of foot ulcers in patients with diabetes. *Diabetes Care* 22:382-387, 1999.
20. Kumar S, Ashe HA, Parnell LN, Fernando DJ, Tsigos C, Young RJ, Ward JD, Boulton AJ. The prevalence of foot ulceration and its correlates in type 2 diabetic patients: a population-based study. *Diabetic Med* 11:480-484, 1994.
21. Moss SE, Klein R, Klein BE. The 14-year incidence of lower-extremity amputations in a diabetic population. The Wisconsin Epidemiologic Study of Diabetic Retinopathy. *Diabetes Care* 22:951-959, 1999.
22. Abbott CA, Vileikyte L, Williamson S, Carrington AL, Boulton AJ. Multicenter study of the incidence of and predictive risk factors for diabetic neuropathic foot ulceration. *Diabetes Care* 21:1071-1075, 1998.
23. Walters DP, Gatling W, Mullee MA, Hill RD. The distribution and severity of diabetic foot disease: a community study with comparison to a non-diabetic group. *Diabet Med* 9:354-358, 1992.
24. Reiber GE, Vileikyte L, Boyko EJ, del Aguila M, Smith DG, Lavery LA, Boulton AJ. Causal pathways for incident lower-extremity ulcers in patients with diabetes from two settings. *Diabetes Care* 22:157-162, 1999.
25. Frykberg RG. Diabetic foot ulcers: pathogenesis and management. *Am Fam Physician* 66:1655-1662, 2002.
26. Frykberg RG, Lavery LA, Pham H, Harvey C, Harkless L, Veves A. Role of neuropathy and high foot pressures in diabetic foot ulceration. *Diabetes Care* 21:1714-1719, 1998.
27. Boyko EJ, Ahroni JH, Stensel V, Forsberg RC, Davignon DR, Smith DG. A prospective study of risk factors for diabetic foot ulcer. The Seattle Diabetic Foot Study. *Diabetes Care* 22:1036-1042, 1999.
28. Pecoraro RE, Reiber GE, Burgess EM. Pathways to diabetic limb amputation: basis for prevention. *Diabetes Care* 13:513-521, 1990.
29. Larsson J, Agardh CD, Apelqvist J, Stenstrom A. Long-term prognosis after healed amputation in patients with diabetes. *Clin Orthop (350)*:149-158, 1998.
30. American Diabetes Association. Consensus Development Conference on Diabetic Foot Wound Care. *Diabetes Care* 22:1354, 1999.
31. Margolis DJ, Allen-Taylor L, Hoffstad O, Berlin JA. Diabetic neuropathic foot ulcers and amputation. *Wound Repair Regen* 13:230-236, 2005.
32. Jeffcoate WJ. The incidence of amputation in diabetes. *Acta Chir Belg* 105:140-144, 2005.
33. Frykberg RG. Epidemiology of the diabetic foot: ulcerations and amputations. *Adv Wound Care* 12:139-141, 1999.
34. Lavery LA, Ashry HR, van Houtum W, Pugh JA, Harkless LB, Basu S. Variation in the incidence and proportion of diabetes-related amputations in minorities. *Diabetes Care* 19:48-52, 1996.
35. Resnick HE, Valsania P, Phillips CL. Diabetes mellitus and nontraumatic lower extremity amputation in black and white Americans: the National Health and Nutrition Examination Survey Epidemiologic Follow-up Study, 1971-1992. *Arch Intern Med* 159:2470-2475, 1999.
36. Tentolouris N, Al-Sabbagh S, Walker MG, Boulton AJ, Jude EB. Mortality in diabetic and nondiabetic patients after amputations performed from 1990 to 1995: a 5-year follow-up study. *Diabetes Care* 27:1598-1604, 2004.
37. Mayfield JA, Reiber GE, Maynard C, Czerniecki JM, Caps MT, Sangeorzan BJ. Survival following lower-limb amputation in a veteran population. *J Rehabil Res Dev* 38:341-345, 2001.
38. Holzer SE, Camerota A, Martens L, Cuedon T, Crystal-Peters J, Zagari M. Costs and duration of care for lower extremity ulcers in patients with diabetes. *Clin Ther* 20:169-181, 1998.
39. Amato D PU, Lantin M, Basso K, Martens L. The cost of illness in patients with diabetic foot ulcers. Abstract, 59th Annual Meeting of the American Diabetes Association, San Diego, 1999.
40. Harrington C, Zagari MJ, Corea J, Klitenic J. A cost analysis of diabetic lower-extremity ulcers. *Diabetes Care* 23:1333-1338, 2000.
41. Gibbons GW, Eliopoulos GM. Infection of the diabetic foot. In: *Management of Diabetic Foot Problems*, p 121, edited by GP Kozak, DR Campbell, RG Frykberg, and GM Habershaw, WB Saunders, Philadelphia, 1995.

42. Shaw JE, Boulton AJ. The pathogenesis of diabetic foot problems: an overview. *Diabetes* 46 (Suppl 2):S58-S61, 1997.
43. Boulton AJ, Meneses P, Ennis WJ. Diabetic foot ulcers: a framework for prevention and care. *Wound Repair Regen* 7:7-16, 1999.
44. Young MJ, Breddy JL, Veves A, Boulton AJ. The prediction of diabetic neuropathic foot ulceration using vibration perception thresholds. A prospective study. *Diabetes Care* 17:557-560, 1994.
45. Pham HT, Armstrong DG, Harvey C, Harkless LB, Giurini JM, Veves A. Screening techniques to identify the at risk patients for developing diabetic foot ulcers in a prospective multicenter trial. *Diabetes Care* 23:606-611, 2000.
46. Abbott CA, Carrington AL, Ashe H, Bath S, Every LC, Griffiths J, Hann AW, Hussein A, Jackson N, Johnson KE, Ryder CH, Torkington R, Van Ross ER, Whalley AM, Widdows P, Williamson S, Boulton AJ. The North-West Diabetes Foot Care Study: incidence of, and risk factors for, new diabetic foot ulceration in a community-based patient cohort. *Diabet Med* 19:377-384, 2002.
47. McNeely MJ, Boyko EJ, Ahroni JH, Stensel VL, Reiber GE, Smith DG, Pecoraro RF. The independent contributions of diabetic neuropathy and vasculopathy in foot ulceration. How great are the risks? *Diabetes Care* 18:216-219, 1995.
48. Mayfield JA, Reiber GE, Sanders LJ, Janisse D, Pogach LM. Preventive foot care in people with diabetes. *Diabetes Care* 21:2161-2177, 1998.
49. Boulton AJ, Kirsner RS, Vileikyte L. Clinical practice. Neuropathic diabetic foot ulcers. *N Engl J Med* 351:48-55, 2004.
50. Boulton AJ. The diabetic foot: from art to science. The 18th Camillo Golgi lecture. *Diabetologia*, 2004.
51. Edmonds ME, Blundell MP, Morris ME, Thomas EM, Cotton LT, Watkins PJ. Improved survival of the diabetic foot: the role of a specialized foot clinic. *Q J Med* 60:763-771, 1986.
52. Akbari CM, Macsata R, Smith BM, Sidawy AN. Overview of the diabetic foot. *Semin Vasc Surg* 16:3-11, 2003.
53. Bus SA, Yang QX, Wang JH, Smith MB, Wunderlich R, Cavanagh PR. Intrinsic muscle atrophy and toe deformity in the diabetic neuropathic foot: a magnetic resonance imaging study. *Diabetes Care* 25:1444-1450, 2002.
54. Sumpio BE. Foot ulcers. *N Engl J Med* 343:787-793, 2000.
55. Van Gils CC, Roeder B. The effect of ankle equinus upon the diabetic foot. *Clin Podiatr Med Surg* 19:391-409, vi, 2002.
56. Lin SS, Lee TH, Wapner KL. Plantar forefoot ulceration with equinus deformity of the ankle in diabetic patients: the effect of tendo-achilles lengthening and total contact casting. *Orthopaedics* 19:465-475, 1996.
57. Lavery LA, Armstrong DG, Vela SA, Quebedeaux TL, Fleischli JG. Practical criteria for screening patients at high risk for diabetic foot ulceration. *Arch Intern Med* 158:158-162, 1998.
58. Armstrong DG, Stacpoole-Shea S, Nguyen H, Harkless LB. Lengthening of the Achilles tendon in diabetic patients who are at high risk for ulceration of the foot. *J Bone Joint Surg Am* 81:535-538, 1999.
59. van Schie CH. A review of the biomechanics of the diabetic foot. *Int J Low Extrem Wounds* 4:160-170, 2005.
60. Lavery LA, Armstrong DG, Boulton AJ. Ankle equinus deformity and its relationship to high plantar pressure in a large population with diabetes mellitus. *J Am Podiatr Med Assoc* 92:479-482, 2002.
61. Mueller MJ, Sinacore DR, Hastings MK, Strube MJ, Johnson JE. Effect of achilles tendon lengthening on neuropathic plantar ulcers. A randomized clinical trial. *J Bone Joint Surg* 85A:1436-1445, 2003.
62. Frykberg R. Diabetic foot ulcerations. In: *The High Risk Foot in Diabetes Mellitus*, 1st ed, pp 151-195, edited by R. Frykberg, Churchill Livingstone, New York, 1991.
63. Flynn MD, Tooke JE. Aetiology of diabetic foot ulceration: a role for the microcirculation. *Diabetic Med* 8:320-329, 1992.
64. Parkhouse N, Le Quesne PM. Impaired neurogenic vascular response in patients with diabetes and neuropathic foot lesions. *N Engl J Med* 318:1306-1309, 1988.
65. Boulton AJM, Vileikyte L. Pathogenesis of diabetic foot ulceration and measurements of neuropathy. *Wounds* 12(Suppl B):12B-18B, 2000.
66. Boulton AJ. The pathogenesis of diabetic foot problems: an overview. *Diabet Med* 13(Suppl 1):S12-16, 1996.
67. Nabuurs-Franssen MH, Houben AJ, Tooke JE, Schaper NC. The effect of polyneuropathy on foot microcirculation in Type II diabetes. *Diabetologia* 45:1164-1171, 2002.
68. Frykberg RG. Biomechanical considerations of the diabetic foot. *Lower Extremity* 2:207-214, 1995.
69. Knox RC, Dutch W, Blume P, Sumpio BE. Diabetic Foot Disease. *Int J Angiology* 9:1-6, 2000.
70. Veves A, Murray HJ, Young MJ, Boulton AJ. The risk of foot ulceration in diabetic patients with high foot pressure: a prospective study. *Diabetologia* 35:660-663, 1992.
71. Robertson DD, Mueller MJ, Smith KE, Commean PK, Pilgram T, Johnson JE. Structural changes in the forefoot of individuals with diabetes and a prior plantar ulcer. *J Bone Joint Surg Am* 84A:1395-1404, 2002.
72. Greenman RL, Khaodhiar L, Lima C, Dinh T, Giurini JM, Veves A. Foot small muscle atrophy is present before the detection of clinical neuropathy. *Diabetes Care* 28:1425-1430, 2005.
73. Mueller MJ, Hastings M, Commean PK, Smith KE, Pilgram TK, Robertson D, Johnson J. Forefoot structural predictors of plantar pressures during walking in people with diabetes and peripheral neuropathy. *J Biomech* 36:1009-1017, 2003.
74. Andersen H, Gjerstad MD, Jakobsen J. Atrophy of foot muscles: a measure of diabetic neuropathy. *Diabetes Care* 27:2382-2385, 2004.
75. Bus SA, Maas M, Cavanagh PR, Michels RP, Levi M. Plantar fat-pad displacement in neuropathic diabetic patients with toe deformity: a magnetic resonance imaging study. *Diabetes Care* 27:2376-2381, 2004.
76. Boulton AJ. Pressure and the diabetic foot: clinical science and offloading techniques. *Am J Surg* 187:17S-24S, 2004.
77. Caputo GM, Cavanagh PR, Ulbrecht JS, Gibbons GW, Karchmer AW. Assessment and management of foot disease in patients with diabetes. *N Engl J Med* 331:854-860, 1994.
78. Armstrong DG, Lavery LA. Elevated peak plantar pressures in patients who have Charcot arthropathy. *J Bone Joint Surg Am* 80:365-369, 1998.
79. Frykberg RG. Charcot arthropathy: pathogenesis and management. *Wounds* 12(6 Suppl B):35B-42B, 2000.
80. Lavery LA, Armstrong DG, Wunderlich RP, Tredwell J, Boulton AJ. Predictive value of foot pressure assessment as part of a population-based diabetes disease management program. *Diabetes Care* 26:1069-1073, 2003.
81. Cavanagh PR, Ulbrecht JS, Caputo GM. New developments in the bio mechanics of the diabetic foot. *Diabetes Metab Res Rev* 16 (Suppl 1):S6-S10, 2000.
82. Murray HJ, Young MJ, Hollis S, Boulton AJ. The association between callus formation, high pressures and neuropathy in diabetic foot ulceration. *Diabetic Med* 13:979-982, 1996.
83. Young MJ, Cavanagh PR, Thomas G, Johnson MM, Murray H, Boulton AJ. The effect of callus removal on dynamic plantar foot pressures in diabetic patients. *Diabet Med* 9:55-57, 1992.
84. Armstrong DG, Lavery LA, Holtz-Neiderer K, Mohler MJ, Wendel CS, Nixon BP, Boulton AJM. Variability in activity may precede diabetic foot lceration. *Diabetes Care* 27:1980-1984, 2004.



85. Apelqvist J, Larsson J, Agardh CD. The influence of external precipitating factors and peripheral neuropathy on the development and outcome of diabetic foot ulcers. *J Diabet Complications* 4:21-25, 1990.
86. Uccioli L, Faglia E, Monticone G, Favales F, Durola L, Aldeghi A, Quarantiello A, Calia P, Menzinger G. Manufactured shoes in the prevention of diabetic foot ulcers. *Diabetes Care* 18:1376-1378, 1995.
87. Pecoraro RE. Chronology and determinants of tissue repair in diabetic lower extremity ulcers. *Diabetes* 40:1305-1313, 1991.
88. Gibbons GW. Lower extremity bypass in patients with diabetic foot ulcers. *Surg Clin North Am* 83:659-669, 2003.
89. Sumpio BE, Lee T, Blume PA. Vascular evaluation and arterial reconstruction of the diabetic foot. *Clin Podiatr Med Surg* 20:689-708, 2003.
90. International Working Group on the Diabetic Foot. International Consensus on the Diabetic Foot, edited by J Apelqvist, K Bakker, WH Van Houtum, MH Nabuurs-Franssen, and NC Schaper. Vol. 2005. International Working Group on the Diabetic Foot, Maastricht, 1999.
91. Mills JL BW, Taylor SM. The diabetic foot: Consequences of delayed treatment and referral. *So Med J* 84:970, 1991.
92. Fernando DJ, Masson EA, Veves A, Boulton AJ. Relationship of limited joint mobility to abnormal foot pressures and diabetic foot ulceration. *Diabetes Care* 14:8-11, 1991.
93. Boulton AJM. The pathway to ulceration. In: *The Foot in Diabetes*, 3rd ed, pp 19-31, edited by AJM Boulton, H Connor, and PR Cavanagh, John Wiley and Sons, Chichester, UK, 2000.
94. Mueller MJ, Diamond JE, Delitto A, Sinacore DR. Insensitivity, limited joint mobility, and plantar ulcers in patients with diabetes mellitus. *Physical Therapy* 69:453-462, 1989.
95. Brownlee M. Glycation products and the pathogenesis of diabetic complications. *Diabetes Care* 15:1835-1843, 1992.
96. Delbridge L, Perry P, Marr S, Arnold N, Yue DK, Turtle JR, Reeve TS. Limited joint mobility in the diabetic foot: relationship to neuropathic ulceration. *Diabet Med* 5:333-337, 1988.
97. Zimny S, Schatz H, Pfohl M. The role of limited joint mobility in diabetic patients with an at-risk foot. *Diabetes Care* 27:942-946, 2004.
98. Grant WP, Foreman EJ, Wilson AS, Jacobus DA, Kukla RM. Evaluation of Young's modulus in Achilles tendons with diabetic neuroarthropathy. *J Am Podiatr Med Assoc* 95:242-246, 2005.
99. Grant WP, Sullivan R, Soenshine DE, Adam M, Slusser JH, Carson KA, Vinik AI. Electron microscopic investigation of the effects of diabetes mellitus on the achilles tendon. *J Foot Ankle Surg* 36:272-278, 1997.
100. Frykberg RG. Diabetic foot ulcerations: management and adjunctive therapy. *Clin Podiatr Med Surg* 20:709-728, 2003.
101. Abouaasha F, van Schie CH, Armstrong DG, Boulton AJ. Plantar soft-tissue thickness predicts high peak plantar pressure in the diabetic foot. *J Am Podiatr Med Assoc* 94:39-42, 2004.
102. Abouaasha F, van Schie CH, Griffiths GD, Young RJ, Boulton AJ. Plantar tissue thickness is related to peak plantar pressure in the high-risk diabetic foot. *Diabetes Care* 24:1270-1274, 2001.
103. D'Ambrogi E, Giurato L, D'Agostino MA, Giacomozzi C, Macellari V, Caselli A, Uccioli L. Contribution of plantar fascia to the increased forefoot pressures in diabetic patients. *Diabetes Care* 26:1525-1529, 2003.
104. D'Ambrogi E, Giacomozzi C, Macellari V, Uccioli L. Abnormal foot function in diabetic patients: the altered onset of Windlass mechanism. *Diabet Med* 22:1713-1719, 2005.
105. Piaggese A, Romanelli M, Schipani E, Campi F, Magliaro A, Baccetti F, Navalesi R. Hardness of plantar skin in diabetic neuropathic feet. *J Diabetes Complications* 13:129-134, 1999.
106. Ahroni JH, Boyko EJ, Forsberg RC. Clinical correlates of plantar pressure among diabetic veterans. *Diabetes Care* 22:965-972, 1999.
107. Rathur HM, Boulton AJ. Pathogenesis of foot ulcers and the need for offloading. *Horm Metab Res* 37(Suppl 1):61-68, 2005.
108. Brand PW. Repetitive stress in the development of diabetic foot ulcers. In: *The Diabetic Foot*, 4th ed, pp 83-90, edited by ME Levin and JK Davidson, Mosby, St Louis, 1988.
109. Habershaw G, Chrzan JS. Biomechanical considerations of the diabetic foot. In: *Management of Diabetic Foot Problems*, 2nd ed, pp 53-65, edited by GP Kozak, DR Campbell, RG Frykberg, and GM Habershaw, WB Saunders, Philadelphia, 1995.
110. Lavery LA, Armstrong DG, Wunderlich RP, Tredwell JL, Boulton AJM. Predictive value of foot pressure assessment as part of a population-based diabetes disease management program. *Diabetes Care* 26:1069-1073, 2003.
111. Pham H, Armstrong DG, Harvey C, Harkless LB, Giurini JM, Veves A. Screening techniques to identify people at high risk for diabetic foot ulceration: a prospective multicenter trial. *Diabetes Care* 23:606-611, 2000.
112. Armstrong DG, Peters EJ, Athanasiou KA, Lavery LA. Is there a critical level of plantar foot pressure to identify patients at risk for neuropathic foot ulceration? *J Foot Ankle Surg* 37:303-307, 1998.
113. Armstrong DG, Lavery LA. Plantar pressures are higher in diabetic patients following partial foot amputation. *Ostomy Wound Manage* 44:30-32, 34, 36 passim, 1998.
114. Shah BR, Hux JE. Quantifying the risk of infectious diseases for people with diabetes. *Diabetes Care* 26:510-513, 2003.
115. Lavery LA, Armstrong DG, Wunderlich RP, Tredwell J, Boulton AJ. Diabetic foot syndrome: evaluating the prevalence and incidence of foot pathology in Mexican Americans and non-Hispanic whites from a diabetes disease management cohort. *Diabetes Care* 26:1435-1438, 2003.
116. Caputo GM, Joshi N, Weitekamp MR. Foot infections in patients with diabetes. *Am Fam Physician* 56:195-202, 1997.
117. Armstrong DG, Lipsky BA. Diabetic foot infections: stepwise medical and surgical management. *Int Wound Journal* 1:123-132, 2004.
118. Grayson ML, Gibbons GW, Habershaw GM, Freeman DV, Pomposelli FB, Rosenblum BI, Levin E, Karchmer AW. Use of ampicillin/sulbactam versus imipenem/cilastatin in the treatment of limb-threatening foot infections in diabetic patients. *Clin Infect Dis* 18:683-693, 1994.
119. Grayson ML. Diabetic foot infections. Antimicrobial therapy. *Infect Dis Clin North Am* 9:143-161, 1995.
120. Sapico FL, Canawati HN, Witte JL, Montgomerie JZ, Wagner FW, Jr, Bessman AN. Quantitative aerobic and anaerobic bacteriology of infected diabetic feet. *J Clin Microbiol* 12:413-420, 1980.
121. Goldstein EJ, Citron DM, Nesbit CA. Diabetic foot infections. Bacteriology and activity of 10 oral antimicrobial agents against bacteria isolated from consecutive cases. *Diabetes Care* 19:638-641, 1996.
122. Lipsky BA. A report from the international consensus on diagnosing and treating the infected diabetic foot. *Diabetes Metab Res Rev* 20(Suppl 1):S68-S77, 2004.
123. Lipsky BA, Berendt AR, Deery HG, Embil JM, Joseph WS, Karchmer AW, LeFrock JL, Lew DP, Mader JT, Norden C, Tan JS. Diagnosis and treatment of diabetic foot infections. *Clin Infect Dis* 39:885-910, 2004.
124. Calhoun JH, Cantrell J, Cobos J, Lacy J, Valdez RR, Hokanson J, Mader JT. Treatment of diabetic foot infections: Wagner classification, therapy, and outcome. *Foot and Ankle* 9:101-106, 1988.
125. Caputo GM. The rational use of antimicrobial agents in diabetic foot infection. In: *The Foot in Diabetes*, 3rd ed, pp 143-151, edited by AJM Boulton, H Connor, and PR Cavanagh, Wiley and Sons, Chichester, 1994.

126. Gibbons GW, Habershaw GM. Diabetic foot infections. *Anatomy and surgery. Infect Dis Clin North Am* 9:131-142, 1995.
127. Eneroth M, Larsson J, Apelqvist J. Deep foot infections in patients with diabetes and foot ulcer: an entity with different characteristics, treatments, and prognosis. *J Diabetes Complications* 13:254-263, 1999.
128. Sinha S, Munichoodapa CS, Kozak GP. Neuroarthropathy (Charcot joints) in diabetes mellitus. *Medicine* 51:191-210, 1972.
129. Sanders LJ, Frykberg RG. Diabetic neuropathic osteoarthropathy: The Charcot foot. In: *The High Risk Foot in Diabetes Mellitus*, pp 325-333, edited by RG Frykberg, Churchill Livingstone, New York, 1991.
130. Jeffcoate W, Lima J, Nobrega L. The Charcot foot. *Diabet Med* 17:253-258, 2000.
131. Banks AS. A clinical guide to Charcot foot. In: *Medical and Surgical Management of the Diabetic Foot*, pp 125-145, edited by S Kominsky, Mosby-Yearbook, St. Louis, 1994.
132. Frykberg RG, Mendezsoon E. Management of the diabetic Charcot foot. *Diabetes Metab Res Rev* 16(Suppl 1):S59-S65, 2000.
133. Sanders L, Frykberg RG. Charcot neuroarthropathy of the foot. In: *Levin and O'Neal's The Diabetic Foot*, 6th ed, pp 439-466, edited by JH Bowker and MA Pfeifer, Mosby, St. Louis, 2001.
134. Frykberg RG, Kozak GP. The diabetic Charcot foot. In: *Management of Diabetic Foot Problems*, 2nd ed, pp 88-97, edited by GP Kozak, DR Campbell DR, RG Frykberg, and GM Habershaw GM, WB Saunders, Philadelphia, 1995.
135. Armstrong DG, Todd WF, Lavery LA, Harkless LB. The natural history of acute Charcot's arthropathy in a diabetic foot specialty clinic. *Diabetic Medicine* 14:357-363, 1997.
136. Frykberg RG. Charcot changes in the diabetic foot. In: *The Diabetic Foot: Medical and Surgical Management*, pp 221-246, edited by A Veves, J Giurini, and FW LoGerfo, Humana Press Inc., Totowa, NJ, 2002.
137. Giurini JM, Chrzan JS, Gibbons GW, Habershaw GM. Charcot's disease in diabetic patients. Correct diagnosis can prevent progressive deformity. *Postgrad Med* 89:163-169, 1991.
138. Pakarinen TK, Laine HJ, Honkonen SE, Peltonen J, Oksala H, Lahtela J. Charcot arthropathy of the diabetic foot. Current concepts and review of 36 cases. *Scand J Surg* 91:195-201, 2002.
139. Rajbhandari SM, Jenkins RC, Davies C, Tesfaye S. Charcot neuroarthropathy in diabetes mellitus. *Diabetologia* 45:1085-1096, 2002.
140. Trepman E, Nihal A, Pinzur MS. Current topics review: Charcot neuroarthropathy of the foot and ankle. *Foot Ankle Int* 26:46-63, 2005.
141. Moss SE, Klein R, Klein BE. The prevalence and incidence of lower extremity amputation in a diabetic population. *Arch Intern Med* 152:610-616, 1992.
142. Adler AI, Boyko EJ, Ahroni JH, Smith DG. Lower-extremity amputation in diabetes. The independent effects of peripheral vascular disease, sensory neuropathy, and foot ulcers [In Process Citation]. *Diabetes Care* 22:1029-1035, 1999.
143. Jeffcoate WJ, van Houtum WH. Amputation as a marker of the quality of foot care in diabetes. *Diabetologia* 47:2051-2058, 2004.
144. Resnick HE, Carter EA, Sosenko JM, Henly SJ, Fabsitz RR, Ness FK, Welty TK, Lee ET, Howard BV. Incidence of lower-extremity amputation in American Indians: the Strong Heart Study. *Diabetes Care* 27:1885-1891, 2004.
145. Moulik PK, Mtonga R, Gill GV. Amputation and mortality in new-onset diabetic foot ulcers stratified by etiology. *Diabetes Care* 26:491-494, 2003.
146. Hennis AJ, Fraser HS, Jonnalagadda R, Fuller J, Chaturvedi N. Explanations for the high risk of diabetes-related amputation in a Caribbean population of black african descent and potential for prevention. *Diabetes Care* 27:2636-2641, 2004.
147. Melton LJ, Macken KM, Palumbo PJ, Elveback LR. Incidence and prevalence of clinical peripheral vascular disease in a population-based cohort of diabetic patients. *Diabetes Care* 3:650-654, 1980.
148. Pirart J. Diabetes mellitus and its degenerative complications: a prospective study of 4,400 patients observed between 1947 and 1973. *Diabetes Care* 1:168, 1978.
149. LoGerfo FW, Gibbons GW, Pomposelli FB, Jr., Campbell DR, Miller A, Freeman DV, Quist WC. Trends in the care of the diabetic foot. Expanded role of arterial reconstruction. *Arch Surg* 127:617-621, discussion 620-621, 1992.
150. Gibbons GW. The diabetic foot: amputations and drainage of infection. *J Vasc Surg* 5:791-793, 1987.
151. Frykberg RG. An evidence-based approach to diabetic foot infections. *Am J Surg* 186:44S-54S, 2003.
152. UK Prospective Diabetes Study Group. Effect of intensive blood-glucose control with metformin on complications in overweight patients with type 2 diabetes (UKPDS 34). UK Prospective Diabetes Study (UKPDS) Group. *Lancet* 352:854-865, 1998.
153. The Diabetes Control and Complications Trial Research Group. The effect of intensive treatment of diabetes on the development and progression of long-term complications in insulin-dependant diabetes mellitus. *N Engl J Med* 329:966-986, 1993.
154. American Diabetes Association. Implications of the Diabetes Control and Complications Trial. *Diabetes Care* 23(Suppl 1):S24-S26, 2000.
155. American Diabetes Association. Implications of the United Kingdom Prospective Diabetes Study. *Diabetes Care* 23(Suppl 1):S27-S31, 2000.
156. Selby JV, Zhang D. Risk factors for lower extremity amputation in persons with diabetes. *Diabetes Care* 18:509-516, 1995.
157. Reiber GE, Pecoraro RE, Koepsell TD. Risk factors for amputation in patients with diabetes mellitus: a case control study. *Ann Intern Med* 117:97-105, 1992.
158. Nelson RG, Gohdes DM, Everhart JE, Hartner JA, Zwemmer FL, Pettitt DJ, Knowler WC. Lower extremity amputations in NIDDM: 12-year follow-up study in Pima Indians. *Diabetes Care* 11:8-16, 1988.
159. Lee JS, Lu M, Lee VS. Lower extremity amputation: incidence, risk factors and mortality in the Oklahoma Indian diabetes study. *Diabetes* 42:876-882, 1993.
160. Lehto S, Ronnema T, Pyorala K, Laakso M. Risk factors predicting lower extremity amputations in patients with NIDDM. *Diabetes Care* 19:607-612, 1996.
161. Humphrey AR, Dowse GK, Thoma K, Zimmet PZ. Diabetes and non-traumatic lower extremity amputations. Incidence, risk factors, and prevention—a 12-year follow-up study in Nauru. *Diabetes Care* 19:710-714, 1996.
162. Levin ME. Preventing amputation in the patient with diabetes. *Diabetes Care* 18:1383-1394, 1995.
163. Frykberg RG. Team approach toward lower extremity amputation prevention in diabetes. *J Am Podiatr Med Assoc* 87:305-312, 1997.
164. Larsson J, Apelqvist J, Agardh CD, Stenstrom A. Decreasing incidence of major amputation in diabetic patients: a consequence of a multidisciplinary foot care team approach? *Diabet Med* 12:770-776, 1995.
165. Driver VR, Madsen J, Goodman RA. Reducing amputation rates in patients with diabetes at a military medical center: the limb preservation service model. *Diabetes Care* 28:248-253, 2005.
166. Van Gils CC, Wheeler LA, Mellstrom M, Brinton EA, Mason S, Wheeler CG. Amputation prevention by vascular surgery and podiatry collaboration in high-risk diabetic and nondiabetic patients. The Operation Desert Foot experience. *Diabetes Care* 22:678-683, 1999.
167. Boyko EJ, Ahroni JH, Stensel V, Forsberg RC, Heagerty PJ. Prediction of diabetic foot ulcer using readily available clinical information: the Seattle Diabetic Foot Study. *Diabetes* 51(Suppl 2):A18, 2002.

168. Apelqvist J, Larsson J, Agardh CD. Long-term prognosis for diabetic patients with foot ulcers. *J Intern Med* 233:485-491, 1993.
169. Ebskov LB. Diabetic amputation and long-term survival. *Int J Rehabil Res* 21:403-408, 1998.
170. Aulivola B, Hile CN, Hamdan AD, Sheahan MG, Veraldi JR, Skillman JJ, Campbell DR, Scovell SD, LoGerfo FW, Pomposelli FB, Jr. Major lower extremity amputation: outcome of a modern series. *Arch Surg* 139:395-399, discussion 399, 2004.
171. Goldner MG. The fate of the second leg in the diabetic amputee. *Diabetes* 9:100-103, 1960.
172. Bodily KC, Burgess EM. Contralateral limb and patient survival after leg amputation. *Am J Surg* 146:280-282, 1983.
173. Sumpio BE, Aruny J, Blume PA. The multidisciplinary approach to limb salvage. *Acta Chir Belg* 104:647-653, 2004.
174. Del Aguila MA, Reiber GE, Koepsell TD. How does provider and patient awareness of high-risk status for lower-extremity amputation influence foot-care practice? *Diabetes Care* 17:1050-1054, 1994.
175. American Diabetes Association. Preventative foot care in people with diabetes. *Diabetes Care* 26(Suppl 1):S78-S79, 2003.
176. Armstrong DG, Perales TA, Murff RT, Edelson GW, Welchon JG. Value of white blood cell count with differential in the acute diabetic foot infection. *J Am Podiatr Med Assoc* 86:224-227, 1996.
177. Caballero E, Frykberg RG. Diabetic foot infections. *J Foot Ankle Surg* 37:248-255, 1998.
178. Eneroth M, Apelqvist J, Stenstrom A. Clinical characteristics and outcome in 223 diabetic patients with deep foot infections. *Foot Ankle Int* 18:716-722, 1997.
179. Keenan AM, Tindel NL, Alavi A. Diagnosis of pedal osteomyelitis in diabetic patients using current scintigraphic techniques. *Arch Intern Med* 149:2262-2266, 1989.
180. Lipsky BA. Osteomyelitis of the foot in diabetic patients. *Clin Infect Dis* 25:1318-1326, 1997.
181. Frykberg RG, Veves A. Diabetic foot infections. *Diabetes Metab Rev* 12:255-270, 1996.
182. Edelson GW, Armstrong DG, Lavery LA, Caicco G. The acutely infected diabetic foot is not adequately evaluated in an inpatient setting. *Arch Intern Med* 156:2373-2376, 1996.
183. Sella EJ, Grosser DM. Imaging modalities of the diabetic foot. *Clin Podiatr Med Surg* 20:729-740, 2003.
184. Edmonds ME, Clarke MB, Newton JB, Barrett J, Watkins PJ. Increased uptake of radiopharmaceutical in diabetic neuropathy. *Q J Med* 57:843-855, 1985.
185. Johnson JE, Kennedy EJ, Shereff MJ, Patel NC, Collier BD. Prospective study of bone, indium-111-labeled white blood cell, and gallium-67 scanning for the evaluation of osteomyelitis in the diabetic foot. *Foot Ankle Int* 17:10-16, 1996.
186. Blume PA, Dey HM, Daley LJ, Arrighi JA, Soufer R, Gorecki GA. Diagnosis of pedal osteomyelitis with Tc-99m HMPAO labeled leukocytes. *J Foot Ankle Surg* 36:120-126, discussion 160, 1997.
187. Devillers A, Moisan A, Hennion F, Garin E, Poirier JY, Bourguet P. Contribution of technetium-99m hexamethylpropylene amine oxime labelled leucocyte scintigraphy to the diagnosis of diabetic foot infection. *Eur J Nucl Med* 25:132-138, 1998.
188. Fox IM, Zeiger L. Tc-99m-HMPAO leukocyte scintigraphy for the diagnosis of osteomyelitis in diabetic foot infections. *J Foot Ankle Surg* 32:591-594, 1993.
189. Newnam LG. Imaging techniques in the diabetic foot. *Clin Podiatr Med Surg* 12:75-86, 1995.
190. Termaat MF, Raijmakers PG, Scholten HJ, Bakker FC, Patka P, Haarman HJ. The accuracy of diagnostic imaging for the assessment of chronic osteomyelitis: a systematic review and meta-analysis. *J Bone Joint Surg Am* 87:2464-2471, 2005.
191. Schauwecker DS, Park HM, Burt RW, Mock BH, Wellman HN. Combined bone scintigraphy and indium-111 leukocyte scans in neuropathic foot disease. *J Nucl Med* 29:1651-1655, 1988.
192. Palestro CJ, Torres MA. Radionuclide imaging in orthopedic infections. *Semin Nucl Med* 27:334-345, 1997.
193. Palestro CJ, Mehta HH, Patel M, Freeman SJ, Harrington WN, Tomas MB, Marwin SE. Marrow versus infection in the Charcot joint: indium-111 leukocyte and technetium-99m sulfur colloid scintigraphy. *J Nucl Med* 39:346-350, 1998.
194. Tomas MB, Patel M, Marwin SE, Palestro CJ. The diabetic foot. *Br J Radiol* 73:443-450, 2000.
195. Aliabadi P, Nikpoor N, Alparslan L. Imaging of neuropathic arthropathy. *Semin Musculoskelet Radiol* 7:217-225, 2003.
196. Boc SF, Brazzo K, Lavian D, Landino T. Acute Charcot foot changes versus osteomyelitis: does Tc-99m HMPAO labeled leukocytes scan differentiate? *J Am Podiatr Med Assoc* 9:365-368, 2001.
197. Longmaid HE, 3rd, Kruskal JB. Imaging infections in diabetic patients. *Infect Dis Clin North Am* 9:163-182, 1995.
198. Zlatkin MB, Pathria M, Sartoris DJ, Resnick D. The diabetic foot. *Radiol Clin North Am* 25:1095-1105, 1987.
199. Savnik A, Amris K, Rogind H, Prip K, Danneskiold-Samsøe B, Bojsen-Møller F, Bartels EM, Bliddal H, Boesen J, Egdud N. MRI of the plantar structures of the foot after falanga torture. *Eur Radiol* 10:1655-1659, 2000.
200. Lipsky BA, Berendt AR, Embil J, De Lalla F. Diagnosing and treating diabetic foot infections. *Diabetes Metab Res Rev* 20(Suppl 1):S56-S64, 2004.
201. Durham JR, Lukens ML, Campanini DS, Wright JG, Smead WL. Impact of magnetic resonance imaging on the management of diabetic foot infections. *Am J Surg* 162:150-153, discussion 153-154, 1991.
202. Ledermann HP, Morrison WB. Differential diagnosis of pedal osteomyelitis and diabetic neuroarthropathy: MR imaging. *Semin Musculoskelet Radiol* 9:272-283, 2005.
203. Berendt AR, Lipsky B. Is this bone infected or not? Differentiating neuro-osteopathy from osteomyelitis in the diabetic foot. *Curr Diab Rep* 4:424-429, 2004.
204. Ahmadi ME, Morrison WB, Carrino JA, Schweitzer ME, Raikin SM, Ledermann HP. Neuropathic arthropathy of the foot with and without superimposed osteomyelitis: MR imaging characteristics. *Radiology* 238:622-631, 2006.
205. Berendt T, Byren I. Bone and joint infection. *Clin Med* 4:510-518, 2004.
206. Morrison WB, Schweitzer ME, Batte WG, Radack DP, Russel KM. Osteomyelitis of the foot: relative importance of primary and secondary MR imaging signs. *Radiology* 207:625-632, 1998.
207. Schweitzer ME, Morrison WB. MR imaging of the diabetic foot. *Radiol Clin North Am* 42:61-71, vi, 2004.
208. Keidar Z, Militianu D, Melamed E, Bar-Shalom R, Israel O. The diabetic foot: initial experience with 18F-FDG PET/CT. *J Nucl Med* 46:444-449, 2005.
209. Alnafisi N, Yun M, Alavi A. F-18 FDG positron emission tomography to differentiate diabetic osteoarthropathy from septic arthritis. *Clin Nucl Med* 26:638-639, 2001.
210. Bureau NJ, Ali SS, Chhem RK, Cardinal E. Ultrasound of musculoskeletal infections. *Semin Musculoskelet Radiol* 2:299-306, 1998.
211. Enderle MD, Coerper S, Schweizer HP, Kopp AE, Thelen MH, Meisner C, Pressler H, Becker HD, Clausen C, Haring HU, Luft D. Correlation of imaging techniques to histopathology in patients with diabetic foot syndrome and clinical suspicion of chronic osteomyelitis. The role of high-resolution ultrasound. *Diabetes Care* 22:294-299, 1999.



212. Kalani M, Brismar K, Fagrell B, Ostergren J, Jorneskog G. Transcutaneous oxygen tension and toe blood pressure as predictors for outcome of diabetic foot ulcers. *Diabetes Care* 22:147-151, 1999.
213. Apelqvist J, Castenfors J, Larsson J, Stenstrom A, Agardh CD. Prognostic value of systolic ankle and toe blood pressure levels in outcome of diabetic foot ulcer. *Diabetes Care* 12:373-378, 1989.
214. Pomposelli FB, Jr., Marcaccio EJ, Gibbons GW, Campbell DR, Freeman DV, Burgess AM, Miller A, LoGerfo FW. Dorsalis pedis arterial bypass: durable limb salvage for foot ischemia in patients with diabetes mellitus. *J Vasc Surg* 21:375-384, 1995.
215. American Diabetes Association. Peripheral arterial disease in people with diabetes. *Diabetes Care* 26:3333-3341, 2003.
216. Young MJ, Adams JE, Anderson GF, Boulton AJ, Cavanagh PR. Medial arterial calcification in the feet of diabetic patients and matched non-diabetic control subjects [see comments]. *Diabetologia* 36:615-621, 1993.
217. Chantelau E, Lee KM, Jungblut R. Association of below-knee atherosclerosis to medial arterial calcification in diabetes mellitus. *Diabetes Res Clin Pract.* 29:169-172, 1995.
218. Stevens MJ, Goss DE, Foster AV, Pitei D, Edmonds ME, Watkins PJ. Abnormal digital pressure measurements in diabetic neuropathic foot ulceration. *Diabet Med* 1:909-915, 1993.
219. Bone GE, Pomajzl MJ. Toe blood pressure by photoplethysmography: an index of healing in forefoot amputation. *Surgery* 5:569, 1981.
220. Karanfilian RG, Lynch TG, Zirul VT, Padberg FT, Jamil Z, Hobson RW, 2nd. The value of laser Doppler velocimetry and transcutaneous oxygen tension determination in predicting healing of ischemic fore foot ulcerations and amputations in diabetic and nondiabetic patients. *J Vasc Surg* 4:511-516, 1986.
221. Arora S, Pomposelli F, LoGerfo FW, Veves A. Cutaneous microcirculation in the neuropathic diabetic foot improves significantly but not completely after successful lower extremity revascularization. *J Vasc Surg* 35:501-505, 2002.
222. Netten PM, Wollersheim H, Thien T, Lutterman JA. Skin microcirculation of the foot in diabetic neuropathy. *Clin Sci (Lond)* 91:559-565, 1996.
223. Adera HM, James K, Castronuovo JJ, Jr, Byrne M, Deshmukh R, Lohr J. Prediction of amputation wound healing with skin perfusion pressure. *J Vasc Surg* 21:823-828, discussion 828-829, 1995.
224. Castronuovo JJ, Jr., Adera HM, Smiell JM, Price RM. Skin perfusion pressure measurement is valuable in the diagnosis of critical limb ischemia. *J Vasc Surg* 26:629-637, 1997.
225. Abularrage CJ, Sidawy AN, White PW, Weiswasser JM, Arora S. Abnormalities of microcirculation in diabetes. In: *Diabetic Foot: Lower Extremity Arterial Disease and Limb Salvage*, pp 145-154, edited by AN. Sidawy, Lippincott Williams & Wilkins, Philadelphia, 2006.
226. LoGerfo FW, Coffman JD. Vascular and microvascular disease of the foot in diabetes. *N Engl J Med* 311:1615-1619, 1984.
227. Andros G. Diagnostic and therapeutic arterial interventions in the ulcerated diabetic foot. *Diabetes Metab Res Rev* 20(Suppl 1):S29-33, 2004.
228. Faglia E, Favales F, Quarantiello A, Calia P, Clelia P, Brambilla G, Rampoldi A, Morabito A. Angiographic evaluation of peripheral arterial occlusive disease and its role as a prognostic determinant for major amputation in diabetic subjects with foot ulcers. *Diabetes Care* 21:625-630, 1998.
229. Hingorani A, Ascher E. Infrapopliteal arterial imaging. In: *Diabetic Foot: Lower Extremity Arterial Disease and Limb Salvage*, pp 155-166, edited by AN Sidawy, Lippincott Williams & Wilkins, Philadelphia, 2006.
230. Lee HM, Wang Y, Sostman HD, Schwartz LH, Khilnani NM, Trost DW, Ramirez de Arellano E, Teeger S, Bush HL. Distal lower extremity arteries: evaluation with two-dimensional MR digital subtraction angiography. *Radiology* 207:505-512, 1998.
231. Stokes KR, Pomposelli FB, Longmaid HE. Arteriography. In: *Management of Diabetic Foot Problems*, 2nd ed, pp 149-157, edited by GP Kozak, Campbell DR, Frykberg RG, and Habershaw GM, WB Saunders, Philadelphia, 1995.
232. Mueller MJ. Identifying patients with diabetes who are at risk for lower extremity complications: use of Semmes-Weinstein monofilaments. *Phys Ther* 76:68-71, 1996.
233. Kumar S, Fernando DJS, Veves A, Knowles EA, Young MJ, Boulton AJM. Semmes-Weinstein monofilaments: a simple, effective and inexpensive screening device for identifying diabetic patients at risk of foot ulceration. *Diabetes Res Clin Practice* 13:63-68, 1991.
234. Armstrong DG, Lavery LA, Vela SA, Quebedeaux TL, Fleischli JG. Choosing a practical screening instrument to identify patients at risk for diabetic foot ulceration. *Arch Intern Med* 158:289-292, 1998.
235. Mayfield JA, Sugarman JR. The use of the Semmes-Weinstein monofilament and other threshold tests for preventing foot ulceration and amputation in persons with diabetes. *J Fam Pract* 49 (11 Suppl):S17-S29, 2000.
236. Coppini DV, Young PJ, Weng C, Macleod AF, Sonksen PH. Outcome on diabetic foot complications in relation to clinical examination and quantitative sensory testing: a case-control study. *Diabet Med* 15:765-771, 1998.
237. Dinh TL, Veves A. A review of the mechanisms implicated in the pathogenesis of the diabetic foot. *Int J Low Extrem Wounds* 4:154-159, 2005.
238. Boulton AJ, Betts RP, Franks CI, Newrick PG, Ward JD, Duckworth T. Abnormalities of foot pressure in early diabetic neuropathy. *Diabet Med* 4:225-228, 1987.
239. Duckworth T, Boulton AJ, Betts RP, Franks CI, Ward JD. Plantar pressure measurements and the prevention of ulceration in the diabetic foot. *J Bone Joint Surg [Br]* 67:79-85, 1985.
240. Pitei DL, Edmonds ME. Foot pressure measurements. *Wounds* 12 Suppl 6:19B-29B, 2000.
241. Donaghue VM, Veves A. Foot pressure measurement. *Orth Phys Ther Clin N Am* 6:1-16, 1997.
242. Harris RI, Beath T. Army Foot Survey—An Investigation of Foot Ailments in Canadian Soldiers. National Research Council of Canada, NRC, Ottawa, No 1574, 1947.
243. van Schie CH, Abbott CA, Vileikyte L, Shaw JE, Hollis S, Boulton AJ. A comparative study of the Podotrack, a simple semiquantitative plantar pressure measuring device, and the optical pedobarograph in the assessment of pressures under the diabetic foot. *Diabet Med* 16:154-159, 1999.
244. Rith-Najarian SJ, Stolusky T, Gohdes DM. Identifying diabetic patients at high risk for lower-extremity amputation in a primary health care setting. A prospective evaluation of simple screening criteria. *Diabetes Care* 15:1386-1389, 1992.
245. Armstrong DG, Lavery LA, Harkless LB. Treatment-based classification system for assessment and care of diabetic feet. *J Am Podiatr Med Assoc* 86:311-316, 1996.
246. Armstrong DG, Lavery LA. Diabetic foot ulcers: prevention, diagnosis and classification. *Am Fam Phys* 57:1325-1340, 1998.
247. Peters EJ, Lavery LA. Effectiveness of the diabetic foot risk classification system of the International Working Group on the Diabetic Foot. *Diabetes Care* 24:1442-1447, 2001.
248. Frykberg RG. Diabetic foot ulcers: current concepts. *J Foot Ankle Surg* 37:440-446, 1998.
249. Barth R, Campbell LV, Allen S, Jupp JJ, Chisholm DJ. Intensive education improves knowledge, compliance, and foot problems in type 2 diabetes. *Diabet Med* 8:111-117, 1991.
250. Calle-Pascual AL, Duran A, Benedi A, Calvo MI, Charro A, Diaz JA, Calle JR, Gil E, Maranes JP, Cabezas-Cerrato J. A preventative foot care programme for people with diabetes with different stages of neuropathy. *Diabetes Res Clin Pract* 57:111-117, 2002.



251. Valk GD, Kriegsman DM, Assendelft WJ. Patient education for preventing diabetic foot ulceration. *Cochrane Database Syst Rev* (1):CD001488, 2005.
252. Frykberg RG. Podiatrist's role in the care and treatment of the diabetic foot. In: *Diabetes 1994*, pp 734-743, edited by S Baba and T Kaneko, Elsevier Science B.V., Amsterdam, 1995.
253. Armstrong DG, Harkless LB. Outcomes of preventative care in a diabetic foot specialty clinic. *J Foot Ankle Surg* 37:460-466, 1998.
254. Ortegon MM, Redekop WK, Niessen LW. Cost-effectiveness of prevention and treatment of the diabetic foot: a Markov analysis. *Diabetes Care* 27:901-907, 2004.
255. Singh N, Armstrong DG, Lipsky BA. Preventing foot ulcers in patients with diabetes. [Review]. *JAMA* 293:217-228, 2005.
256. Bild DE, Shelby JV, Sinnock P, Browner WS, Braveman P, Showstock JA. Lower extremity amputations in people with diabetes: epidemiology and prevention. *Diabetes Care* 12:24-29, 1989.
257. Rith-Najarian SJ, Reiber GE. Prevention of foot problems in persons with diabetes. *J Fam Pract* 49 (11 Suppl):S30-39, 2000.
258. Reiber GE, Raugi GJ. Preventing foot ulcers and amputations in diabetes. *Lancet* 366:1676-1677, 2005.
259. Lavery LA, Vela SA, Fleischli JG, Armstrong DG, Lavery DC. Reducing plantar pressure in the neuropathic foot: a comparison of footwear. *Diabetes Care* 20:1706-1710, 1997.
260. Cavanagh PR. Therapeutic footwear for people with diabetes. *Diabetes Metab Res Rev* 20(Suppl 1):S51-S55, 2004.
261. Mueller MJ. Therapeutic footwear helps protect the diabetic foot. *J Am Pod Med Assoc* 87:360-364, 1997.
262. Chantelau E, Kushner T, Spraul M. How effective is cushioned therapeutic footwear in protecting diabetic feet? A clinical study. *Diabetic Medicine* 7:335-339, 1990.
263. Reiber GE, Smith DG, Wallace C, Sullivan K, Hayes S, Vath C, Maciejewski ML, Yu O, Heagerty PJ, LeMaster J. Effect of therapeutic footwear on foot reulceration in patients with diabetes: a randomized controlled trial. *JAMA* 287:2552-2558, 2002.
264. Maciejewski ML, Reiber GE, Smith DG, Wallace C, Hayes S, Boyko EJ. Effectiveness of Diabetic Therapeutic Footwear in Preventing Reulceration. *Diabetes Care* 27:1774-1782, 2004.
265. Mueller MJ, Strube MJ, Allen BT. Therapeutic footwear can reduce plantar pressures in patients with diabetes and transmetatarsal amputation. *Diabetes Care* 20:637-641, 1997.
266. Brown D, Wertsch JJ, Harris GF, Klein J, Janisse D. Effect of rocker soles on plantar pressures. *Arch Phys Med Rehabil* 85:81-86, 2004.
267. Boulton AJ, Jude EB. Therapeutic footwear in diabetes: the good, the bad, and the ugly? *Diabetes Care* 27:1832-1833, 2004.
268. Dahmen R, Haspels R, Koomen B, Hoeksma AF. Therapeutic footwear for the neuropathic foot: an algorithm. *Diabetes Care* 24:705-709, 2001.
269. Tovey FI. The manufacture of diabetic footwear. *Diabet Med* 1:69-71, 1984.
270. Armstrong DG, Frykberg RG. Classifying diabetic foot surgery: toward a rational definition. *Diabet Med* 20:329-331, 2003.
271. Frykberg R, Giurini J, Habershaw G, Rosenblum B, Chrzan J. Prophylactic surgery in the diabetic foot. In: *Medical and Surgical Management of the Diabetic Foot*, pp.399-439, edited by SJ Kominsky, Mosby, St. Louis, 1993.
272. Giurini JM, Lyons TE. Diabetic foot complications: diagnosis and management. *Int J Low Extrem Wounds* 4:171-182, 2005.
273. Sayner LR, Rosenblum BI, Giurini JM. Elective surgery of the diabetic foot. *Clin Podiatr Med Surg* 20(4):783-792, 2003.
274. Malone JM, Snyder M, Anderson G, Bernhard VM, Holloway GA, Jr., Bunt TJ. Prevention of amputation by diabetic education. *Am J Surg* 158:520-523, discussion 523-524, 1989.
275. American Diabetes Association. Standards of medical care in diabetes—2006. *Diabetes Care* 29(Suppl 1):S4-42, 2006.
276. American Diabetes Association. Preventive foot care in diabetes. *Diabetes Care* 27(Suppl 1):S63-S64, 2004.
277. Lavery LA, Higgins KR, Lanctot DR, Constantinides GP, Zamorano RG, Armstrong DG, Athanasiou KA, Agrawal CM. Home monitoring of foot skin temperatures to prevent ulceration. *Diabetes Care* 27:2642-2647, 2004.
278. Dargis V, Pantelejeva O, Jonushaite A, Vileikyte L, Boulton AJ. Benefits of a multidisciplinary approach in the management of recurrent diabetic foot ulceration in Lithuania: a prospective study. *Diabetes Care* 22:1428-1431, 1999.
279. Faglia E, Favales F, Morabito A. New ulceration, new major amputation, and survival rates in diabetic subjects hospitalized for foot ulceration from 1990 to 1993: a 6.5-year follow-up. *Diabetes Care* 24:78-83, 2001.
280. Preventive foot care in people with diabetes. *Diabetes Care* 26(Suppl 1):16-17, 2003.
281. Mayfield JA, Reiber GE, Sanders LJ, Janisse D, Pogach LM. Preventive foot care in diabetes. *Diabetes Care* 27(Suppl 1):S63-S64, 2004.
282. Litzelman DK, Slemenda CW, Langefeld CD, Hays LM, Welch MA, Bild DE, Ford ES, Vinicor F. Reduction of lower extremity clinical abnormalities in patients with non-insulin-dependent diabetes mellitus. A randomized, controlled trial. *Ann Intern Med* 119:36-41, 1993.
283. Collins KA, Sumpio BE. Vascular assessment. *Clin Podiatr Med Surg* 17:171-191, 2000.
284. Akbari CM, Sidawy AN. Overview of the Diabetic Foot and Limb Salvage. In: *Diabetic Foot: Lower Extremity Arterial Disease and Limb Salvage*, pp 1-10, edited by AN Sidawy, Lippincott Williams & Wilkins, Philadelphia, 2006.
285. Grayson ML, Gibbons GW, Balogh K, Levin E, Karchmer AW. Probing to bone in infected pedal ulcers. A clinical sign of underlying osteomyelitis in diabetic patients. *JAMA* 273:721-723, 1995.
286. Wrobel JS, Connolly JE. Making the diagnosis of osteomyelitis. The role of prevalence. *J Am Podiatr Med Assoc* 88:337-343, 1998.
287. Lipsky BA. Medical treatment of diabetic foot infections. *Clin Infect Dis* 39(Suppl 2):S104-S114, 2004.
288. Lazarus GS, Cooper DM, Knighton DR, Margolis DJ, Pecoraro RE, Rodeheaver G, Robson MC. Definitions and guidelines for assessment of wounds and evaluation of healing. *Arch Dermatol* 130:489-493, 1994.
289. Young MJ. Classification of ulcers and its relevance to management. In: *The Foot in Diabetes*, 3rd ed, pp 61-72, edited by AJM Boulton, H Connor, and PR Cavanagh, John Wiley and Sons, Chichester, 2000.
290. Armstrong DG, Lavery LA, Harkless LB. Validation of a diabetic wound classification system. The contribution of depth, infection, and ischemia to risk of amputation [see comments]. *Diabetes Care* 21:855-859, 1998.
291. Lavery LA, Armstrong DG, Harkless LB. Classification of Diabetic Foot Wounds. *J Foot Ankle Surg* 35:528-531, 1996.
292. Wagner FW. The dysvascular foot: a system for diagnosis and treatment. *Foot and Ankle* 2:64-122, 1981.
293. Oyibo SO, Jude EB, Tarawneh I, Nguyen HC, Harkless LB, Boulton AJ. A comparison of two diabetic foot ulcer classification systems: the Wagner and the University of Texas wound classification systems. *Diabetes Care* 24:84-88., 2001.
294. Schaper NC. Diabetic foot ulcer classification system for research purposes: a progress report on criteria for including patients in research studies. *Diabetes Metab Res Rev* 20(Suppl 1):S90-S95, 2004.
295. Markowitz JS, Gutterman EM, Magee G, Margolis DJ. Risk of amputation in patients with diabetic foot ulcers: a claims-based study. *Wound Repair Regen* 14:11-17, 2006.
296. Patout CA, Jr., Birke JA, Horswell R, Williams D, Cerise FP. Effectiveness of a comprehensive diabetes lower-extremity amputation prevention program in a predominantly low-income African-American population. *Diabetes Care* 23:1339-1342, 2000.

297. Ollendorf DA, Kotsanos JG, Wishner WJ, Friedman M, Cooper T, Bittoni M, Oster G. Potential economic benefits of lower-extremity amputation prevention strategies in diabetes. *Diabetes Care* 21:1240-1245, 1998.
298. Apelqvist J, Ragnarson-Tennvall G, Larsson J, Persson U. Long-term costs for foot ulcers in diabetic patients in a multidisciplinary setting. *Foot Ankle Int* 16:388-394, 1995.
299. Frykberg RG. The team approach in diabetic foot management. *Adv Wound Care* 11:71-77, 1998.
300. Holstein PE, Sorensen S. Limb salvage experience in a multidisciplinary diabetic foot unit. *Diabetes Care* 22 (Suppl 2):B97-B103, 1999.
301. Wraight PR, Lawrence SM, Campbell DA, Colman PG. Creation of a multidisciplinary, evidence based, clinical guideline for the assessment, investigation and management of acute diabetes related foot complications. *Diabet Med* 22:127-136, 2005.
302. Driver VR. Silver dressings in clinical practice. *Ostomy Wound Manage* 50(9A Suppl):11S-15S, 2004.
303. Nelson JP. The vascular history and physical examination. *Clin Podiatr Med Surg* 9:1-17, 1992.
304. Ramasastry SS. Chronic problem wounds. *Clin Plastic Surg* 25:367-396, 1998.
305. Gibbons GW, Marcaccio EJ, Jr, Burgess AM, Pomposelli FB, Jr, Freeman DV, Campbell DR, Miller A, LoGerfo FW. Improved quality of diabetic foot care, 1984 vs 1990. Reduced length of stay and costs, insufficient reimbursement. *Arch Surg* 128:576-581, 1993.
306. Aulivola B, Pomposelli FB. Dorsalis pedis, tarsal and plantar artery bypass. *J Cardiovasc Surg (Torino)* 45:203-212, 2004.
307. Pomposelli FB, Kansal N, Hamdan AD, Belfield A, Sheahan M, Campbell DR, Skillman JJ, Logerfo FW. A decade of experience with dorsalis pedis artery bypass: analysis of outcome in more than 1000 cases. *J Vasc Surg* 37:307-315, 2003.
308. Cook SD, Ryaby JP, McCabe J, Frey JJ, Heckman JD, Kristiansen TK. Acceleration of tibia and distal radius fracture healing in patients who smoke. *Clin Orthop Relat Res* 337:198-207, 1997.
309. Silverstein P. Smoking and wound healing. *Am J Med* 93:22S-24S, 1992.
310. Vileikyte L, Peyrot M, Bundy C, Rubin RR, Leventhal H, Mora P, Shaw JE, Baker P, Boulton AJ. The development and validation of a neuropathy- and foot ulcer-specific quality of life instrument. *Diabetes Care* 26:2549-2555, 2003.
311. Vileikyte L, Rubin RR, Leventhal H. Psychological aspects of diabetic neuropathic foot complications: an overview. *Diabetes Metab Res Rev* 20(Suppl 1):S13-S18, 2004.
312. Schultz GS, Sibbald RG, Falanga V, Ayello EA, Dowsett C, Harding K, Romanelli M, Stacey MC, Teot L, Vanscheidt W. Wound bed preparation: a systematic approach to wound management. *Wound Repair Regen* 11(Suppl 1):S1-S28, 2003.
313. O'Brien M. Methods of debridement and patient focused care. *J Comm Nurs* 17:17-25, 2003.
314. Falanga V. Wound healing and its impairment in the diabetic foot. *Lancet* 366:1736-1743, 2005.
315. Falanga V. Wound bed preparation: science applied to practice. European Wound Management Association (EWMA). Position Document: Wound Bed Preparation in Practice, pp 2-5, 2004.
316. Bucknall TE. The effect of local infection upon wound healing: an experimental study. *Br J Surg* 67:851-855, 1980.
317. Robson MC, Stenberg BD, Heggors JP. Wound healing alterations caused by infection. *Clin Plast Surg* 17:485-492, 1990.
318. Bowering CK. Diabetic foot ulcers. Pathophysiology, assessment, and therapy. *Can Fam Physician* 47:1007-1016, 2001.
319. Enoch S, Harding K. Wound bed preparation: the science behind the removal of barrier to healing. *Wounds* 15:213-229, 2003.
320. Edmonds M, Foster A, Vowden P. Wound bed preparation for diabetic foot ulcers. European Wound Management Association (EWMA). Position Document: Wound Bed Preparation in Practice, pp 6-11, 2004.
321. Miller M. The role of debridement in wound healing. *Community Nurse* 2:52-55, 1996.
322. Levin M. Diabetic foot wounds: pathogenesis and management. *Adv Wound Care* 10:24-30, 1997.
323. Steed DL, Donohoe D, Webster MW, Lindsley L. Effect of extensive debridement and treatment on the healing of diabetic foot ulcers. Diabetic Ulcer Study Group. *J Am Coll Surg* 183:61-64, 1996.
324. Sieggreen MY, Maklebust J. Debridement: choices and challenges. *Adv Wound Care* 10:32-37, 1997.
325. Driver VR. Treating the macro and micro wound environment of the diabetic patient: managing the whole patient, not the hole in the patient. *Foot and Ankle Quarterly—The Seminar Journal* 16:47-56, 2004.
326. Steed D. Modulating wound healing in diabetes. In: Levin and O'Neal's *The Diabetic Foot*, pp 395-404, edited by J Bowker and M Pfeiffer, Mosby, St. Louis, 2001.
327. Attinger CE, Bulan E, Blume PA. Surgical debridement: the key to successful wound healing and reconstruction. *Clin Podiatr Med Surg* 17:599-630, 2000.
328. Falanga V. Wound bed preparation and the role of enzymes: a case for multiple actions of therapeutic agents. *Wounds* 14:47-57, 2002.
329. Webb L. High Pressure Parallel Fluid Flow for Debridement of Contaminated Wounds in a Pig Model. HydroCision Doc. No. 1000-1173, Belreric, MA, 2003.
330. Webb L, Smith T, Morykwas M. A Pilot Study of Two Techniques for Wound Debridement. HydroCision Doc. No. 1000-1255, Bellerica, MA, 2003.
331. Hsu C, Bereuing K. Wound Debridement Using VERSAJET A Novel Hydrosurgery System. HydroCision Doc. No. 1000-1232, Bellerica, MA, 2003.
332. Jung W, Winter H. Considerations for the use of Clostridial collagenase in clinical practice. *Clin Drug Invest* 15:245-252, 1998.
333. Drager E, Winter H. Surgical debridement versus enzymatic debridement. In: *The Clinical Relevance of Debridement*, pp 59-71, edited by M Baharestani, F Gottrup, P Holstein, and W Vanscheidt, Springer-Verlag, New York, 1999.
334. Ayello E, Cuddigan J. Debridement: controlling the necrotic/cellular burden. *Adv Skin Wound Care* 17:66-75, 2004.
335. Alvarez OM, Fernandez-Obregon A, Rogers RS, Bergamo L, Masso J, Black M. A prospective, randomized, comparative study of collagenase and papain-urea for pressure ulcer debridement. *Wounds* 14:293-301, 2002.
336. Eaglstein WH, Falanga V. Chronic wounds. *Surg Clin North Am* 77:689-700, 1997.
337. Scott RG, Loehne HB. 5 questions—and answers—about pulsed lavage. *Adv Skin Wound Care* 13:133-134, 2000.
338. Frost & Sullivan Research Service. Market Engineering Analysis of the Enzymatic Wound Debridement Products Market, 1998.
339. Armstrong DG, Mossel J, Short B, Nixon BP, Knowles EA, Boulton AJ. Maggot debridement therapy: a primer. *J Am Podiatr Med Assoc* 92:398-401, 2002.
340. Mumcuoglu KY. Clinical applications for maggots in wound care. *Am J Clin Dermatol* 2:219-227, 2001.
341. Sherman RA. Maggot therapy for foot and leg wounds. *Int J Low Extrem Wounds* 1:135-142, 2002.
342. Sherman RA. Maggot therapy for treating diabetic foot ulcers unresponsive to conventional therapy. *Diabetes Care* 26:446-451, 2003.
343. Courtney M. The use of larval therapy in wound management in the UK. *J Wound Care* 8:177-179, 1999.

344. Hinman CD, Maibach H. Effect of air exposure and occlusion on experimental human skin wounds. *Nature* 200;377-378, 1963.
345. Winter GD. Formation of the scab and the rate of epithelization of superficial wounds in the skin of the young domestic pig. *Nature* 193:293-294, 1962.
346. Bucalo B, Eaglstein WH, Falanga V. Inhibition of cell proliferation by chronic wound fluid. *Wound Repair Regen* 1:181-186, 1993.
347. Falanga V. Classifications for wound bed preparation and stimulation of chronic wounds. *Wound Repair Regen* 8:347-352, 2000.
348. Phillips TJ, al-Amoudi HO, Leverkus M, Park HY. Effect of chronic wound fluid on fibroblasts. *J Wound Care* 7:527-532, 1998.
349. Hansson C. Interactive wound dressings. A practical guide to their use in older patients. *Drugs Aging* 11:271-284, 1997.
350. Dinh T, Pham H, Veves A. Emerging treatments in diabetic wound care. *Wounds* 14:2-10, 2002.
351. Veves A, Sheehan P, Pham HT. A randomized, controlled trial of Promogran (a collagen/oxidized regenerated cellulose dressing) vs standard treatment in the management of diabetic foot ulcers. *Arch Surg* 137:822-827, 2002.
352. Ovington LG. Overview of matrix metalloprotease modulation and growth factor protection in wound healing. Part 1. *Ostomy Wound Manage* 48(6 Suppl):3-7, 2002.
353. Falanga V. Introducing the concept of wound bed preparation. *Inter Forum Wound Care* 16:1-4, 2001.
354. Lobmann R, Schultz G, Lehnert H. Proteases and the diabetic foot syndrome: mechanisms and therapeutic implications. *Diabetes Care* 28:461-471, 2005.
355. Mulder GD, Vande Berg JS. Cellular senescence and matrix metalloproteinase activity in chronic wounds. Relevance to debridement and new technologies. *J Am Podiatr Med Assoc* 92:34-37, 2002.
356. Rosner K, Ross C, Karlsmark T, Petersen AA, Gottrup F, Vejlsgaard GL. Immunohistochemical characterization of the cutaneous cellular infiltrate in different areas of chronic leg ulcers. *Apmis* 103:293-299, 1995.
357. Tarnuzzer RW, Schultz GS. Biochemical analysis of acute and chronic wound environments. *Wound Repair Regen* 4:321-325, 1996.
358. Driver VR, Landowski M, Madsen J. The diabetic foot: from assessment to treatment. In: *Acute and Chronic Wounds: Nursing Management*, 3rd ed, pp 307-336, edited by R Bryant, Mosby, St. Louis, 2004.
359. Jeffcoate WJ, Harding KG. Diabetic foot ulcers. *Lancet* 361:1545-1551, 2003.
360. Mulder G, Armstrong DG, Seaman S. Standard appropriate and advanced care: medical legal considerations for diabetic lower extremity wounds. *Wounds* 26:1069-1073, 2003.
361. Wieman TJ. Clinical efficacy of becaplermin (rhPDGF-BB) gel. Becaplermin Gel Studies Group. *Am J Surg* 176(2A Suppl):74S-79S, 1998.
362. Wieman TJ, Smiell JM, Su Y. Efficacy and safety of a topical gel formulation of recombinant human platelet-derived growth factor-BB (becaplermin) in patients with chronic neuropathic diabetic ulcers. A phase III randomized placebo-controlled double-blind study. *Diabetes Care* 21:822-827, 1998.
363. Li V, Kung E, Li W. Molecular therapies for wounds: modalities for stimulating angiogenesis and granulation. In: *The Wound Management Manual*, pp 17-43, edited by B Lee, McGraw-Hill, New York, 2005.
364. Knighton DR, Ciresi KF, Fiegel VD, Austin LL, Butler EL. Classification and treatment of chronic nonhealing wounds: successful treatment with autologous platelet-derived wound healing factors (PDWHF). *Ann Surg* 204:332-330, 1986.
365. Bennett NT, Schultz GS. Growth factors and wound healing: Part II. Role in normal and chronic wound healing. *Am J Surg* 166:74-81, 1993.
366. Falanga V, Shen J. Growth factors, signal transduction and cellular responses. In: *Cutaneous Wound Healing*, pp 81-93, edited by V Falanga, Martin Dunitz Ltd, London, 2001.
367. Robson M, Smith P. Topical use of growth factors to enhance healing. In: *Cutaneous Wound Healing*, pp 379-398, edited by V Falanga, Martin Dunitz Ltd, London, 2001.
368. Hogge J, Krasner D, Nguyen HC, Harkless LB, Armstrong DG. The potential benefits of advanced therapeutic modalities in the treatment of diabetic foot wounds. *J Am Podiatr Med Assoc* 90:57-65, 2000.
369. Margolis DJ, Kantor J, Santanna J, Strom BL, Berlin JA. Effectiveness of platelet releasate for the treatment of diabetic neuropathic foot ulcers. *Diabetes Care* 24:483-488, 2001.
370. Bello YM, Falabella AF, Eaglstein WH. Tissue-engineered skin. Current status in wound healing. *Am J Clin Dermatol* 2:305-313, 2001.
371. Veves A, Falanga V, Armstrong DG, Sabolinski ML. Graftskin, a human skin equivalent, is effective in the management of noninfected neuropathic diabetic foot ulcers: a prospective randomized multicenter clinical trial. *Apligraf Diabetic Foot Ulcer Study*. *Diabetes Care* 24:290-295, 2001.
372. Gentzkow GD, Iwasaki SD, Hershon KS. Use of Dermagraft, a cultured human dermis, to treat diabetic foot ulcers. *Diabetes Care* 19:350-354, 1996.
373. Marston WA, Hanft J, Norwood P, Pollak R. The efficacy and safety of Dermagraft in improving the healing of chronic diabetic foot ulcers: results of a prospective randomized trial. *Diabetes Care* 26:1701-1705, 2003.
374. Brem H, Balledux J, Bloom T, Kerstein MD, Hollier L. Healing of diabetic foot ulcers and pressure ulcers with human skin equivalent: a new paradigm in wound healing. *Arch Surg* 135:627-634, 2000.
375. Edmonds M, Bates M, Doxford M, Gough A, Foster A. New treatments in ulcer healing and wound infection. *Diabetes Metab Res Rev* 16(Suppl 1):S51-S54, 2000.
376. Falanga V, Sabolinski M. A bilayered living skin construct (APLIGRAF) accelerates complete closure of hard-to-heal venous ulcers. *Wound Repair Regen* 7:201-207, 1999.
377. Donohue K, Falanga V. Skin substitutes in acute and chronic wounds. In: *The Wound Management Manual*, pp 298-308, edited by B Lee, McGraw-Hill, New York, 2005.
378. Frykberg RG, Hodde JP. Biomaterial wound matrix from small intestine submucosa: review and efficacy in diabetic wound healing. In: *The Wound Management Manual*, pp 290-297, edited by B Lee, McGraw-Hill, New York, 2005.
379. Niezgodna JA, Van Gils CC, Frykberg RG, Hodde JP. Randomized clinical trial comparing OASIS Wound Matrix to Regranex Gel for diabetic ulcers. *Adv Skin Wound Care* 18:258-266, 2005.
380. Gottlieb M, Furman J. Successful Management and Surgical Closure of Chronic and Pathological Wounds Using Integra®. *J Burns Surg Wound Care monograph* Vol 3, 2004.
381. Brigido S. Healing Debilitating Diabetic Foot Ulcers. *Orthopedic Technology Review*, 6(6), Ascend Media, Los Angeles, 2004.
382. Bakker DJ. Hyperbaric oxygen therapy and the diabetic foot. *Diabetes Metab Res Rev* 16(Suppl 1):S55-S58, 2000.
383. Cianci P. Advances in the treatment of the diabetic foot: is there a role for adjunctive hyperbaric oxygen therapy? *Wound Repair Regen* 12:2-10, 2004.
384. Kranke P, Bennett M, Roeckl-Wiedmann I. Hyperbaric oxygen therapy for chronic wounds (Cochrane Review). *Cochrane Database Syst Rev* 2, 2003.



385. Niinikoski J. Hyperbaric oxygen therapy of diabetic foot ulcers, tran-  
scutaneous oxymetry in clinical decision making. *Wound Repair  
Regen* 11:458-461, 2003.
386. Strauss MB. Hyperbaric oxygen as an intervention for managing  
wound hypoxia: its role and usefulness in diabetic foot wounds. *Foot  
Ankle Int* 26:15-18, 2005.
387. Zamboni WA, Wong HP, Stephenson LL, Pfeifer MA. Evaluation of  
hyperbaric oxygen for diabetic wounds: a prospective study. *Undersea Hyperb Med* 24:175-179, 1997.
388. Wunderlich RP, Peters EJ, Lavery LA. Systemic hyperbaric oxygen  
therapy: lower-extremity wound healing and the diabetic foot. *Diabetes Care* 23:1551-1555, 2000.
389. O'Meara S, Cullum N, Majid M, Sheldon T. Systematic reviews of  
wound care management: (3) antimicrobial agents for chronic  
wounds; (4) diabetic foot ulceration. *Health Technol Assess* 4:1-237,  
2000.
390. Ennis WJ, Foremann P, Mozen N, Massey J, Conner-Kerr T, Meneses  
P. Ultrasound therapy for recalcitrant diabetic foot ulcers: results of a  
randomized, double-blind, controlled, multicenter study. *Ostomy  
Wound Manage* 51:24-39, 2005.
391. Thawer HA, Houghton PE. Effects of ultrasound delivered through a  
mist of saline to wounds in mice with diabetes mellitus. *J Wound Care*  
13:171-176, 2004.
392. Torke K. Healing wounds through ultrasound. *Podiatry Management*,  
130-134, Nov-Dec 2004.
393. Armstrong DG, Attinger CE, Boulton AJ, Frykberg RG, Kirsner RS,  
Lavery LA, Mills JL. Guidelines regarding negative wound therapy  
(NPWT) in the diabetic foot. *Ostomy Wound Manage* 50(4B Suppl):3S-27S, 2004.
394. Armstrong DG, Lavery LA, Abu-Rumman P, Espensen EH, Vazquez  
JR, Nixon BP, Boulton AJ. Outcomes of subatmospheric pressure  
dressing therapy on wounds of the diabetic foot. *Ostomy Wound  
Manage* 48:64-68, 2002.
395. DeFranzo AJ, Argenta LC, Marks MW, Molnar JA, David LR, Webb  
LX, Ward WG, Teasdall RG. The use of vacuum-assisted closure  
therapy for the treatment of lower-extremity wounds with exposed  
bone. *Plast Reconstr Surg* 108:1184-1191, 2001.
396. Espensen EH, Nixon BP, Lavery LA, Armstrong DG. Use of  
subatmospheric (VAC) therapy to improve bioengineered tissue  
grafting in diabetic foot wounds. *J Am Podiatr Med Assoc*  
92:395-397, 2002.
397. McCallon SK, Knight CA, Valiulus JP, Cunningham MW, McCulloch  
JM, Farinas LP. Vacuum-assisted closure versus saline-moistened  
gauze in the healing of postoperative diabetic foot wounds. *Ostomy  
Wound Manage* 46:28-32, 34, 2000.
398. Argenta LC, Morykwas MJ. Vacuum-assisted closure: a new method  
for wound control and treatment: clinical experience. *Ann Plast Surg*  
38:563-576, discussion 577, 1997.
399. Morykwas MJ, Argenta LC, Shelton-Brown EI, McGuirt W. Vacuum-  
assisted closure: a new method for wound control and treatment:  
animal studies and basic foundation. *Ann Plast Surg* 38:553-562,  
1997.
400. Hess CL, Howard MA, Attinger CE. A review of mechanical adjuncts  
in wound healing: hydrotherapy, ultrasound, negative pressure  
therapy, hyperbaric oxygen, and electrostimulation. *Ann Plast Surg*  
51:210-218, 2003.
401. Niezgoda JA, Schibly B. Negative-pressure wound therapy (vacuum-  
assisted closure). In: *The Wound Management Manual*, pp 65-71,  
edited by B Lee, McGraw-Hill, New York, 2005.
402. DeFranzo AJ, Marks MW, Argenta LC, Genecov DG. Vacuum-  
assisted closure for the treatment of degloving injuries. *Plast Reconstr  
Surg* 104:2145-2148, 1999.
403. Saltzman CL. Salvage of diffuse ankle osteomyelitis by single-stage  
resection and circumferential frame compression arthrodesis. *Iowa  
Orthop J* 25:47-52, 2005.
404. Webb LX. New techniques in wound management: vacuum-assisted  
wound closure. *J Am Acad Orthop Surg* 10:303-311, 2002.
405. Yuan-Innes MJ, Temple CL, Lacey MS. Vacuum-assisted wound  
closure: a new approach to spinal wounds with exposed hardware.  
*Spine* 26:E30-E33, 2001.
406. Blackburn JH, 2nd, Boemi L, Hall WW, Jeffords K, Hauck RM,  
Banducci DR, Graham WP, 3rd. Negative-pressure dressings as a  
bolster for skin grafts. *Ann Plast Surg* 40:453-457, 1998.
407. Greer SE, Longaker MT, Margiotta M, Mathews AJ, Kasabian A. The  
use of subatmospheric pressure dressing for the coverage of radial  
forearm free flap donor-site exposed tendon complications. *Ann Plast  
Surg* 43:551-554, 1999.
408. Scherer LA, Shiver S, Chang M, Meredith JW, Owings JT. The  
vacuum assisted closure device: a method of securing skin grafts and  
improving graft survival. *Arch Surg* 137:930-933, discussion  
933-934, 2002.
409. Venturi ML, Attinger CE, Mesbahi AN, Hess CL, Graw KS.  
Mechanisms and clinical applications of the vacuum-assisted closure  
(VAC) device: a review. *Am J Clin Dermatol* 6:185-194, 2005.
410. Armstrong DG, Lavery LA. Negative pressure wound therapy after  
partial diabetic foot amputation: a multicentre, randomised controlled  
trial. *Lancet* 366:1704-1710, 2005.
411. Kloth LC, McCulloch JM. Promotion of wound healing with  
electrical stimulation. *Adv Wound Care* 9:42-45, 1996.
412. McCulloch JM. Electrical Stimulation in Wound Repair. In: *The  
Wound Management Manual*, pp 80-89, edited by B Lee, McGraw-  
Hill, New York, 2005.
413. Lundeberg TCM, Eriksson V, Malm M. Electrical nerve stimulation  
improves healing of diabetic ulcers. *Annals of Plastic Surgery*  
29:328-331, 1992.
414. Armstrong DG, Nguyen HC, Lavery LA, van Schie CH, Boulton  
AJM, Harkless LB. Offloading the diabetic foot wound: a randomized  
clinical trial. *Diabetes Care* 24:1019-1022, 2001.
415. Armstrong DG, Lavery LA, Nixon BP, Boulton AJM. It is not what  
you put on, but what you take off: techniques for debriding and  
offloading the diabetic foot wound. *Clin Infect Dis* 39:S92-99, 2004.
416. Brem H, Sheehan P, Boulton AJ. Protocol for treatment of diabetic  
foot ulcers. *Am J Surg* 187:1S-10S, 2004.
417. Armstrong DG, Lavery LA, Wu S, Boulton AJ. Evaluation of remov-  
able and irremovable cast walkers in the healing of diabetic foot  
wounds: a randomized controlled trial. *Diabetes Care* 28:551-554,  
2005.
418. Cavanagh PR, Lipsky BA, Bradbury AW, Botek G. Treatment for  
diabetic foot ulcers. *Lancet* 366:1725-1735, 2005.
419. Zimny S, Schatz H, Pfohl U. The effects of applied felted foam on  
wound healing and healing times in the therapy of neuropathic  
diabetic foot ulcers. *Diabet Med* 20:622-625, 2003.
420. Birke JA, Pavich MA, Patout Jr CA, Horswell R. Comparison of  
forefoot ulcer healing using alternative off-loading methods in  
patients with diabetes mellitus. *Adv Skin Wound Care* 15:210-215,  
2002.
421. Zimny S, Reinsch B, Schatz H, Pfohl M. Effects of felted foam on  
plantar pressures in the treatment of neuropathic diabetic foot ulcers.  
*Diabetes Care* 24:2153-2154, 2001.
422. Katz IA, Harlan A, Miranda-Palma B, Prieto-Sanchez L, Armstrong  
DG, Bowker JH, Mizel MS, Boulton AJM. A randomized trial of two  
irremovable offloading devices in the management of neuropathic  
diabetic foot ulcers. *Diabetes Care* 28:555-559, 2005.
423. Newman LG, Waller J, Palestro CJ, Schwartz M, Klein MJ, Hermann  
G, Harrington E, Harrington M, Roman SH, Stagnaro-Green A.  
Unsuspected osteomyelitis in diabetic foot ulcers. diagnosis and  
monitoring by leukocyte scanning with indium in 111 oxyquinoline.  
*JAMA* 266:1246-1251, 1991.



424. Vileikyte L, Leventhal H, Gonzalez JS, Peyrot M, Rubin RR, Ulbrecht JS, Garrow A, Waterman C, Cavanagh PR, Boulton AJ. Diabetic peripheral neuropathy and depressive symptoms: the association revisited. *Diabetes Care* 28:2378-2383, 2005.
425. Armstrong DG, Lavery LA, Kimbriel HR, Nixon BP, Boulton AJ. Activity patterns of patients with diabetic foot ulceration: patients with active ulceration may not adhere to a standard pressure off-loading regimen. *Diabetes Care* 26:2595-2597, 2003.
426. Nwomeh BC, Yager DR, Cohen IK. Physiology of the chronic wound. *Clin Plast Surg* 25:341-356, 1998.
427. Reiber GE. The epidemiology of diabetic foot problems. *Diabet Med* 13(Suppl 1):S6-S11, 1996.
428. Sapico FL, Bessman AN. Diabetic foot infections. In: *High Risk Foot in Diabetes Mellitus*, pp 197-211, edited by RG Frykberg, Churchill Livingstone Inc., New York, 1991.
429. Frykberg RG. Diabetic foot infections: evaluation and management. *Adv Wound Care* 11:329-331, 1998.
430. Karchmer AW, Gibbons GW. Foot infections in diabetes: evaluation and management. *Curr Clin Top Infect Dis* 14:1-22, 1994.
431. Edelson GW, Armstrong DG, Lavery LA, Caicco G. The acutely infected diabetic foot is not adequately evaluated in an inpatient setting. *J Am Podiatr Med Assoc* 87:260-265, 1997.
432. Wheat LJ, Allen SD, Henry M, Kernek CB, Siders JA, Kuebler T, Fineberg N, Norton J. Diabetic foot infections. Bacteriologic analysis. *Arch Intern Med* 146:1935-1940, 1986.
433. Mackowiak PA, Jones SR, Smith JW. Diagnostic value of sinus-tract cultures in chronic osteomyelitis. *JAMA* 239:2772-2775, 1978.
434. Slater RA, Lazarovitch T, Boldur I, Ramot Y, Buchs A, Weiss M, Hindi A, Rapoport MJ. Swab cultures accurately identify bacterial pathogens in diabetic foot wounds not involving bone. *Diabet Med* 21:705-709, 2004.
435. Jeffcoate WJ, Lipsky BA. Controversies in diagnosing and managing osteomyelitis of the foot in diabetes. *Clin Infect Dis* 39 (Suppl 2):S115-S122, 2004.
436. Zuluaga AF, Galvis W, Saldarriaga JG, Agudelo M, Salazar BE, Vesga O. Etiologic diagnosis of chronic osteomyelitis: a prospective study. *Arch Intern Med* 166:95-100, 2006.
437. Mont MA, Waldman BJ, Hungerford DS. Evaluation of preoperative cultures before second-stage reimplantation of a total knee prosthesis complicated by infection. A comparison-group study. *J Bone Joint Surg Am* 82A:1552-1557, 2000.
438. Lipsky BA, Itani K, Norden C. Treating foot infections in diabetic patients: a randomized, multicenter, open-label trial of linezolid versus ampicillin-sulbactam/amoxicillin-clavulanate. *Clin Infect Dis* 38:17-24, 2004.
439. Wakefield MC, Kan VL, Arora S, Weiswasser JM, Sidawy AN. Nonoperative management of diabetic foot infections. In: *Diabetic Foot: Lower Extremity Arterial Disease and Limb Salvage*, pp 43-48, edited by AN Sidawy, Lippincott Williams & Wilkins, Philadelphia, 2006.
440. Hartemann-Heurtier A, Robert J, Jacqueminet S, Ha Van G, Golmard JL, Jarlier V, Grimaldi A. Diabetic foot ulcer and multidrug-resistant organisms: risk factors and impact. *Diabet Med* 21:710-715, 2004.
441. Watkins PJ, Edmonds ME. Sympathetic nerve failure in diabetes. *Diabetologia* 25:73-77, 1983.
442. Yuh WT, Corson JD, Baraniewski HM, Rezai K, Shamma AR, Kathol MH, Sato Y, el-Khoury GY, Hawes DR, Platz CE, et al. Osteomyelitis of the foot in diabetic patients: evaluation with plain film, 99mTc-MDP bone scintigraphy, and MR imaging. *AJR Am J Roentgenol* 152:795-800, 1989.
443. Morrison WB, Ledermann HP. Work-up of the diabetic foot. *Radiol Clin North Am* 40:1171-1192, 2002.
444. Lipsky BA, Pecoraro RE, Larson SA, Hanley ME, Ahroni JH. Outpatient therapy of diabetic foot infection. *Arch Intern Med* 150:790-797, 1990.
445. Tan JS. Foot Infections in Diabetic Patients. *Curr Infect Dis Rep* 6:377-379, 2004.
446. Williams DT, Hilton JR, Harding KG. Diagnosing foot infection in diabetes. *Clin Infect Dis* 39 Suppl 2:S83-86, 2004.
447. Dang CN, Prasad YD, Boulton AJ, Jude EB. Methicillin-resistant *Staphylococcus aureus* in the diabetic foot clinic: a worsening problem. *Diabet Med* 20:159-161, 2003.
448. Tentolouris N, Jude EB, Smirnof I, Knowles EA, Boulton AJ. Methicillin-resistant *Staphylococcus aureus*: an increasing problem in a diabetic foot clinic. *Diabet Med* 16:767-771, 1999.
449. Edmonds M. Infection in the neuroischemic foot. *Int J Low Extrem Wounds* 4:145-153, 2005.
450. Lipsky BA, Berendt AR. Principles and practice of antibiotic therapy of diabetic foot infections. *Diabetes Metab Res Rev* 16(Suppl 1): S42-S46, 2000.
451. Ansari MA, Shukla VK. Foot infections. *Int J Low Extrem Wounds* 4:74-87, 2005.
452. International Working Group on the Diabetic Foot. International Consensus on the Diabetic Foot. International Working Group on the Diabetic Foot. International Diabetes Federation, Noordwijkerhout, Netherlands, 2003.
453. Armstrong DG, Lavery LA, Sariaya M, Ashry H. Leukocytosis is a poor indicator of acute osteomyelitis of the foot in diabetes mellitus. *J Foot Ankle Surg* 35:280-283, 1996.
454. Leibovici L, Yehezkeili Y, Porter A, Regev A, Krauze I, Harell D. Influence of diabetes mellitus and glycaemic control on the characteristics and outcome of common infections. *Diabet Med* 13:457-463, 1996.
455. Lipsky BA, Pecoraro RE, Wheat LJ. The diabetic foot: soft tissue and bone infection. *Infect Dis. Clin. N. Am* 4:409-432, 1990.
456. Dickhaut SC, DeLee JC, Page CP. Nutritional status: importance in predicting wound-healing after amputation. *J Bone Joint Surg* 66A:71-75, 1984.
457. Leichter SB, Allweiss P, Harley J, Clay J, Kuperstein-Chase J, Sweeney GJ, Kolkin J. Clinical characteristics of diabetic patients with serious pedal infections. *Metabolism* 37(2 Suppl 1):22-24, 1988.
458. Apelqvist J, Larsson J. What is the most effective way to reduce incidence of amputation in the diabetic foot? *Diabetes Metab Res Rev* 16(Suppl 1):S75-S83, 2000.
459. Edmonds ME. Experience in a multidisciplinary diabetic foot clinic. In: *The Foot in Diabetes*, pp 121-131, edited by H Connor, AJM Boulton, and JD Ward JD, John Wiley and Sons, Chichester, 1987.
460. Gottrup F. Management of the diabetic foot: surgical and organisational aspects. *Horm Metab Res* 37 (Suppl 1):69-75, 2005.
461. Hartemann-Heurtier A, Ha Van G, Danan JP, Koskas F, Jacqueminet S, Golmard JL, Grimaldi A. Outcome of severe diabetic foot ulcers after standardised management in a specialised unit. *Diabetes Metab* 28:477-484, 2002.
462. Tan JS, Friedman NM, Hazelton-Miller C, Flanagan JP, File TM, Jr. Can aggressive treatment of diabetic foot infections reduce the need for above-ankle amputation? *Clin Infect Dis* 23:286-291, 1996.
463. van Baal JG. Surgical treatment of the infected diabetic foot. *Clin Infect Dis* 39(Suppl 2):S123-S128, 2004.
464. Scher KS, Steele FJ. The septic foot in patients with diabetes. *Surgery* 104:661-666, 1988.
465. Armstrong DG, Liswood PJ, Todd WF. 1995 William J. Stickle Bronze Award. Prevalence of mixed infections in the diabetic pedal wound. A retrospective review of 112 infections [published erratum appears in *J am Podiatr Med Assoc* 1995 Nov85(11)695]. *J Am Podiatr Med Assoc* 85:533-537, 1995.

466. Lipsky BA, Armstrong DG, Citron DM, Tice AD, Morgenstern DE, Abramson MA. Ertapenem versus piperacillin/tazobactam for diabetic foot infections (SIDESTEP): prospective, randomised, controlled, double-blinded, multicentre trial. *Lancet* 366:1695-1703, 2005.
467. Caputo GM. The rational use of antimicrobial agents in diabetic foot infection. In: *The Foot in Diabetes*, 3rd ed, pp 143-151, edited by AJM Boulton, H Connor, and PR Cavanagh, John Wiley and Sons, Chichester; 2000.
468. Lipsky BA, Baker PD, Landon GC, Fernau R. Antibiotic therapy for diabetic foot infections: comparison of two parenteral-to-oral regimens. *Clin Infect Dis* 24:643-648, 1997.
469. Lew DP, Waldvogel FA. Osteomyelitis. *Lancet* 364:369-379, 2004.
470. Ha Van G, Siney H, Danan JP, Sachon C, Grimaldi A. Treatment of osteomyelitis in the diabetic foot: contribution of conservative surgery. *Diabetes Care* 19:1257-1260, 1996.
471. Walenkamp GH, Kleijn LL, de Leeuw M. Osteomyelitis treated with gentamicin-PMMA beads: 100 patients followed for 1-12 years. *Acta Orthop Scand* 69:518-522, 1998.
472. Roeder B, Van Gils CC, Maling S. Antibiotic beads in the treatment of diabetic pedal osteomyelitis. *J Foot Ankle Surg* 39:124-130, 2000.
473. Armstrong DG, Findlow AH, Oyibo SO, Boulton AJ. The use of absorbable antibiotic-impregnated calcium sulphate pellets in the management of diabetic foot infections. *Diabet Med* 18:942-943, 2001.
474. Saltzman CL, Hagy ML, Zimmerman B, Estin M, Cooper R. How effective is intensive nonoperative initial treatment of patients with diabetes and Charcot arthropathy of the feet? *Clin Orthop Relat Res* (435):185-190, 2005.
475. Brower AC, Allman RM. Pathogenesis of the neurotrophic joint: neurotraumatic vs. neurovascular. *Radiology* 139:349-354, 1981.
476. Edelman SV, Kosofsky EM, Paul RA, Kozak GP. Neuro-osteoarthropathy (Charcot's joint) in diabetes mellitus following revascularization surgery. Three case reports and a review of the literature. *Arch Intern Med* 147:1504-1508, 1987.
477. Johnson JT. Neuropathic fractures and joint injuries. Pathogenesis and rationale of prevention and treatment. *J Bone Joint Surg Am* 49:1-30, 1967.
478. Frykberg RG, Zgonis T. The diabetic Charcot foot. In: *Diabetic Foot: Lower Extremity Arterial Disease and Limb Salvage*, pp 117-128, edited by AN Sidawy, Lippincott Williams & Wilkins, Philadelphia, 2006.
479. Jeffcoate WJ. Abnormalities of vasomotor regulation in the pathogenesis of the acute charcot foot of diabetes mellitus. *Int J Low Extrem Wounds* 4:133-137, 2005.
480. Young MJ, Marshall A, Adams JE, Selby PL, Boulton AJ. Osteopenia, neurological dysfunction, and the development of Charcot neuroarthropathy. *Diabetes Care* 18:34-38, 1995.
481. Frykberg RG, Kozak GP. Neuropathic arthropathy in the diabetic foot. *Am Fam Physician* 17:105, 1978.
482. Stevens MJ, Edmonds ME, Foster AV, Watkins PJ. Selective neuropathy and preserved vascular responses in the diabetic Charcot foot. *Diabetologia* 35:148-154, 1992.
483. Petrova NL, Foster AV, Edmonds ME. Calcaneal bone mineral density in patients with Charcot neuropathic osteoarthropathy: differences between Type 1 and Type 2 diabetes. *Diabet Med* 22:756-761, 2005.
484. Petrova NL, Foster AV, Edmonds ME. Difference in presentation of charcot osteoarthropathy in type 1 compared with type 2 diabetes. *Diabetes Care* 27:1235-1236, 2004.
485. Jeffcoate W. Vascular calcification and osteolysis in diabetic neuropathy-is RANK-L the missing link? *Diabetologia* 47:1488-1492, 2004.
486. Jeffcoate WJ, Game F, Cavanagh PR. The role of proinflammatory cytokines in the cause of neuropathic osteoarthropathy (acute Charcot foot) in diabetes. *Lancet* 366:2058-2061, 2005.
487. Hofbauer LC, Kuhne CA, Viereck V. The OPG/RANKL/RANK system in metabolic bone diseases. *J Musculoskelet Neuronal Interact* 4:268-275, 2004.
488. Hofbauer LC, Schoppet M. Clinical implications of the osteoprotegerin/RANKL/RANK system for bone and vascular diseases. *JAMA* 292:490-495, 2004.
489. Armstrong DG, Peters EJ. Charcot's arthropathy of the foot. *J Am Podiatr Med Assoc* 92:390-394, 2002.
490. Slater RA, Ramot Y, Buchs A, Rapoport MJ. The diabetic Charcot foot. *Isr Med Assoc J* 6:280-283, 2004.
491. Banks AS, McGlamry ED. Charcot Foot. *J Am Podiatr Med Assoc* 79:213-217, 1989.
492. Hopfner S, Krolak C, Kessler S, Tiling R, Brinkbaumer K, Hahn K, Dresel S. Preoperative imaging of Charcot neuroarthropathy in diabetic patients: comparison of ring PET, hybrid PET, and magnetic resonance imaging. *Foot Ankle Int* 25:890-895, 2004.
493. Caputo GM, Ulbrecht J, Cavanagh PR, Juliano P. The Charcot foot in diabetes: six key points. *Am Fam Physician* 57:2705-2710, 1998.
494. Chantelau E. The perils of procrastination: effects of early vs. delayed detection and treatment of incipient Charcot fracture. *Diabet Med* 22:1707-1712, 2005.
495. Eichenholz SN. In *Charcot Joints*, pp 1-20, Charles C. Thomas, Springfield, 1966.
496. Schauwecker DS. The scintigraphic diagnosis of osteomyelitis. *Am J Roentgenol* 158:9, 1992.
497. Gough A, Abbraha H, Li F, Purewal TS, Foster AV, Watkins PJ, Moniz C, Edmonds ME. Measurement of markers of osteoclast and osteoblast activity in patients with acute and chronic diabetic Charcot neuroarthropathy. *Diabet Med* 14:527-531, 1997.
498. Jude EB, Selby PL, Burgess J, Lilleystone P, Mawer EB, Page SR, Donohoe M, Foster AV, Edmonds ME, Boulton AJ. Bisphosphonates in the treatment of Charcot neuroarthropathy: a double-blind randomised controlled trial. *Diabetologia* 44:2032-2037, 2001.
499. Pitocco D, Ruotolo V, Caputo S, Mancini L, Collina CM, Manto A, Caradonna P, Ghirlanda G. Six-month treatment with alendronate in acute Charcot neuroarthropathy: a randomized controlled trial. *Diabetes Care* 28:1214-1215, 2005.
500. Sella EJ, Barrette C. Staging of Charcot neuroarthropathy along the medial column of the foot in the diabetic patient. *J Foot Ankle Surg* 38:34-40, 1999.
501. Yu GV, Hudson JR. Evaluation and treatment of stage 0 Charcot's neuroarthropathy of the foot and ankle. *J Am Podiatr Med Assoc* 92:210-220, 2002.
502. Shibata T, Tada K, Hashizume C. The results of arthrodesis of the ankle for leprotic neuroarthropathy. *J Bone Joint Surg* 72A:749-756, 1990.
503. Schon LC, Marks RM. The management of neuroarthropathic fracture-dislocations in the diabetic patient. *Orthop Clin North Am* 26:375-392, 1995.
504. Schon LC, Easley ME, Weinfeld SB. Charcot neuroarthropathy of the foot and ankle. *Clin Orthop Relat Res* (349):116-131, 1998.
505. Brodsky JW, Rouse AM. Exostectomy for symptomatic bony prominences in diabetic Charcot feet. *Clin Orthop Relat Res* 296:21-26, 1993.
506. Brodsky JW. The diabetic foot. In: *Surgery of the Foot and Ankle*, pp 877-958, edited by RA Mann and M Coughlin, CV Mosby, St. Louis, 1992.
507. Sanders L, Frykberg R. Charcot foot. In: *The Diabetic Foot*, 5th ed, pp 149-180, edited by ME Levin, LW O'Neal, and JH Bowker, Mosby-Yearbook, Inc., St. Louis, 1993.

508. Pinzur MS, Shields N, Trepman E, Dawson P, Evans A. Current practice patterns in the treatment of Charcot foot. *Foot Ankle Int* 21:916-920, 2000.
509. Lesko P, Maurer RC. Talonavicular dislocations and midfoot arthropathy in neuropathic diabetic feet. Natural course and principles of treatment. *Clin Orthop Relat Res* (240):226-231, 1989.
510. Pinzur M. Surgical versus accommodative treatment for Charcot arthropathy of the midfoot. *Foot Ankle Int* 25:545-549, 2004.
511. Pinzur MS, Sage R, Stuck R, Kaminsky S, Zmuda A. A treatment algorithm for neuropathic (Charcot) midfoot deformity. *Foot Ankle* 14:189-197, 1993.
512. Myerson MS, Henderson MR, Saxby T, Short KW. Management of midfoot diabetic neuroarthropathy. *Foot Ankle Int* 15:233-241, 1994.
513. Giurini JM. Applications and use of in-shoe orthoses in the conservative management of Charcot foot deformity. *Clin Podiatr Med Surg* 11:271-278, 1994.
514. Morgan JM, Biehl WC, 3rd, Wagner FW, Jr. Management of neuropathic arthropathy with the Charcot restraint orthotic walker. *Clin Orthop Relat Res* (296):58-63, 1993.
515. Mehta JA, Brown C, Sargeant N. Charcot restraint orthotic walker. *Foot Ankle Int* 19:619-623, 1998.
516. Armstrong DG, Short B, Nixon BP, Boulton AJM. Technique for fabrication of an "instant" total contact cast for treatment of neuropathic diabetic foot ulcers. *J Amer Podiatr Med Assoc* 92:405-408, 2002.
517. Saltzman CL, Johnson KA, Goldstein RH, Donnelly RE. The patellar tendon-bearing brace as treatment for neurotrophic arthropathy: a dynamic force monitoring study. *Foot Ankle* 13:14-21, 1992.
518. Guse ST, Alvine FG. Treatment of diabetic foot ulcers and Charcot neuroarthropathy using the patellar tendon-bearing brace. *Foot Ankle Int* 18:675-677, 1997.
519. Anderson JJ, Woelffer KE, Holtzman JJ, Jacobs AM. Bisphosphonates for the treatment of Charcot neuroarthropathy. *J Foot Ankle Surg* 43:285-289, 2004.
520. Frykberg RG. Charcot foot: an update on pathogenesis and management. In: *The Foot in Diabetes*, 3rd ed, pp 235-260, edited by AJM Boulton, H Connors H and PR Cavanagh PR, John Wiley, London, 2000.
521. Selby PL, Young MJ, Boulton AJ. Bisphosphonates: a new treatment for diabetic Charcot neuroarthropathy? *Diabetic Medicine* 11:28-31, 1994.
522. Hanft JR, Goggin JP, Landsman A, Surprenant M. The role of combined magnetic field bone growth stimulation as an adjunct in the treatment of neuroarthropathy/Charcot joint: an expanded pilot study. *J Foot Ankle Surg* 37:510-515, discussion 550-511, 1998.
523. Bier RR, Estersohn HS. A new treatment for Charcot joint in the diabetic foot. *J Am Podiatr Med Assoc* 77:63-69, 1987.
524. Grady JF, O'Connor KJ, Axe TM, Zager EJ, Dennis LM, Brenner LA. Use of electrostimulation in the treatment of diabetic neuroarthropathy. *J Am Podiatr Med Assoc* 90:287-294, 2000.
525. Strauss E, Gonya G. Adjunct low intensity ultrasound in Charcot neuroarthropathy. *Clin Orthop Relat Res* (349):132-138, 1998.
526. Jolly GP, Zgonis T, Polyzois V. External fixation in the management of Charcot neuroarthropathy. *Clin Podiatr Med Surg* 20:741-756, 2003.
527. Pinzur MS. Benchmark analysis of diabetic patients with neuropathic (Charcot) foot deformity. *Foot Ankle Int* 20:564-567, 1999.
528. Fabrin J, Larsen K, Holstein PE. Long-term follow-up in diabetic Charcot feet with spontaneous onset. *Diabetes Care* 23:796-800, 2000.
529. Newman JH. Spontaneous dislocation in diabetic neuropathy. A report of six cases. *J Bone Joint Surg Br* 61-B:484-488, 1979.
530. Simon SR, Tejwani SG, Wilson DL, Santner TJ, Denniston NL. Arthrodesis as an early alternative to nonoperative management of charcot arthropathy of the diabetic foot. *J Bone Joint Surg Am* 82A:939-950, 2000.
531. Baravarian B, Van Gils CC. Arthrodesis of the Charcot foot and ankle. *Clin Podiatr Med Surg North Am* 21:271-289, 2004.
532. Rosenblum BI, Giurini JM, Miller LB, Chrzan JS, Habershaw GM. Neuropathic ulcerations plantar to the lateral column in patients with Charcot foot deformity: a flexible approach to limb salvage. *J Foot Ankle Surg* 36:360-363, 1997.
533. Caravaggi C, Cimmino M, Caruso S, Dalla Noce S. Intramedullary compressive nail fixation for the treatment of severe charcot deformity of the ankle and rear foot. *J Foot Ankle Surg* 45:20-24, 2006.
534. Sayner LR, Rosenblum BI. External fixation for Charcot foot reconstruction. *Curr Surg* 62:618-623, 2005.
535. Pinzur MS, Noonan T. Ankle arthrodesis with a retrograde femoral nail for Charcot ankle arthropathy. *Foot Ankle Int* 26(7):545-549, 2005.
536. Cooper PS. Application of external fixators for management of Charcot deformities of the foot and ankle. *Foot Ankle Clin* 7:207-254, 2002.
537. Resch S. Corrective surgery in diabetic foot deformity. *Diabetes Metab Res Rev* 20(Suppl 1):S34-S36, 2004.
538. Wang JC. Use of external fixation in the reconstruction of the Charcot foot and ankle. *Clin Podiatr Med Surg* 20:97-117, 2003.
539. Wang JC, Le AW, Tsukuda RK. A new technique for Charcot's foot reconstruction. *J Am Podiatr Med Assoc* 92:429-436, 2002.
540. Mendicino RW, Catanzariti AR, Saltrick KR, Dombek MF, Tullis BL, Statler TK, Johnson BM. Tibiotalocalcaneal arthrodesis with retro grade intramedullary nailing. *J Foot Ankle Surg* 43:82-86, 2004.
541. Myerson MS, Alvarez RG, Lam PW. Tibiocalcaneal arthrodesis for the management of severe ankle and hindfoot deformities. *Foot Ankle Int* 21:643-650, 2000.
542. Myerson MS, Edwards WH. Management of neuropathic fractures in the foot and ankle. *J Am Acad Orthop Surg* 7:8-18, 1999.
543. Stefansky SA, Rosenblum BI. The Charcot foot: a clinical challenge. *Int J Low Extrem Wounds* 4:183-187, 2005.
544. Nicklas BJ. Prophylactic surgery in the diabetic foot. In: *The High Risk Foot in Diabetes Mellitus*, pp 537-538, edited by RG Frykberg, Churchill Livingstone, New York, 1991.
545. Baravarian B, Menendez MM, Weinheimer DJ, Lowery C, Kosanovich R, Vidt L. Subtotal calcaneotomy for the treatment of large heel ulceration and calcaneal osteomyelitis in the diabetic patient. *J Foot Ankle Surg* 38:194-202, 1999.
546. Bollinger M, Thordarson DB. Partial calcaneotomy: an alternative to below knee amputation. *Foot Ankle Int* 23:927-932, 2002.
547. Catanzariti AR, Blich EL, Karlock LG. Elective foot and ankle surgery in the diabetic patient. *J Foot Ankle Surg* 35:23-41, 1995.
548. Catanzariti AR, Mendicino R, Haverstock B. Osteotomy for diabetic neuroarthropathy involving the midfoot. *J Foot Ankle Surg* 39:291-300, 2000.
549. Frykberg RG, Piaggese A, Donaghue VM, Schipani E, Habershaw GM, Navalesi R, Veves A. Difference in treatment of foot ulcerations in Boston, USA and Pisa, Italy. *Diabetes Res Clin Pract* 35:21-26, 1997.
550. Giacalone VF, Krych SM, Harkless LB. The university of texas health science center at San Antonio: experience with foot surgery in diabetics. *J Foot Ankle Surg* 33:590-597, 1994.
551. Giurini JM, Habershaw GM, Chrzan JS. Panmetatarsal head resection in chronic neuropathic ulceration. *J Foot Surg* 26:249-252, 1987.

552. Holstein P, Lohmann M, Bitsch M, Jorgensen B. Achilles tendon lengthening, the panacea for plantar forefoot ulceration? *Diabetes Metab Res Rev* 20(Suppl 1):S37-S40, 2004.
553. Laing P. Prophylactic orthopaedic surgery—is there a role? In: *The Foot in Diabetes*, 3rd ed, pp 261-277, edited by AJM Boulton, H Connor, and PR Cavanagh, John Wiley & Sons, Chichester, 2002.
554. Piaggese A, Schipani E, Campi F, Romanelli M, Baccetti F, Arvia C, Navalesi R. Conservative surgical approach versus non-surgical management for diabetic neuropathic foot ulcers: a randomized trial. *Diabet Med* 15:412-417, 1998.
555. Rosenblum BI, Giurini JM, Chrzan JS, Habershaw GM. Preventing loss of the great toe with the hallux interphalangeal joint arthroplasty. *J Foot Ankle Surg* 33:557-560, 1994.
556. Ruth Chaytor E. Surgical treatment of the diabetic foot. *Diabetes Metab Res Rev* 16(Suppl 1):S66-S69, 2000.
557. Tillo TH, Giurini JM, Habershaw GM, Chrzan JS, Rowbotham JL. Review of metatarsal osteotomies for the treatment of neuropathic ulcerations. *J Am Podiatr Med Assoc* 80:211-217, 1990.
558. Blume PA, Paragas LK, Sumpio BE, Attinger CE. Single-stage surgical treatment of noninfected diabetic foot ulcers. *Plast Reconstr Surg* 109:601-609, 2002.
559. Attinger CE, Ducic I, Cooper P, Zelen CM. The role of intrinsic muscle flaps of the foot for bone coverage in foot and ankle defects in diabetic and nondiabetic patients. *Plast Reconstr Surg* 110:1047-1054, discussion 1055-1047, 2002.
560. Colen LB, Replogle SL, Mathes SJ. The V-Y plantar flap for reconstruction of the forefoot. *Plast Reconstr Surg* 81:220-228, 1988.
561. Roukis TS, Zgonis T. Modifications of the great toe fibular flap for diabetic forefoot and toe reconstruction. *Ostomy Wound Manage* 51:30-32, 34, 36 passim, 2005.
562. Roukis TS, Zgonis T. Skin grafting techniques for soft-tissue coverage of diabetic foot and ankle wounds. *J Wound Care* 14:173-176, 2005.
563. Jolly GP, Zgonis T, Blume P. Soft tissue reconstruction of the diabetic foot. *Clin Podiatr Med Surg* 20:757-781, 2003.
564. Ger R. Wound management by constant tension approximation. *Ostomy Wound Manage* 42:40-46, 1996.
565. Ger R, Schessel ES. Prevention of major amputations in nonischemic lower limb lesions. *J Am Coll Surg* 201:898-905, 2005.
566. Eginton MT, Brown KR, Seabrook GR, Towne JB, Cambria RA. A prospective randomized evaluation of negative-pressure wound dressings for diabetic foot wounds. *Ann Vasc Surg* 17:645-649, 2003.
567. Armstrong DG, Lavery LA, Stern S, Harkless LB. Is prophylactic diabetic foot surgery dangerous? *J Foot Ankle Surg* 35:585-589, 1996.
568. Barry DC, Sabacinski KA, Habershaw GM, Giurini JM, Chrzan JS. Tendo Achillis procedures for chronic ulcerations in diabetic patients with transmetatarsal amputations. *J Am Podiatr Med Assoc* 83:96-100, 1993.
569. Giurini JM, Rosenblum BI. The role of foot surgery in patients with diabetes. *Clin Podiatr Med Surg* 12:119-127, 1995.
570. Nishimoto GS, Attinger CE, Cooper PS. Lengthening the Achilles tendon for the treatment of diabetic plantar forefoot ulceration. *Surg Clin North Am* 83:707-726, 2003.
571. Mayfield JA, Reiber GE, Sanders LJ, Janisse D, Pogach LM. Preventive foot care in people with diabetes [see comments]. *Diabetes Care* 21:2161-2177, 1998.
572. Attinger C, Venturi M, Kim K, Ribiero C. Maximizing length and optimizing biomechanics in foot amputations by avoiding cookbook recipes for amputation. *Semin Vasc Surg* 16:44-66, 2003.
573. Sage R, Doyle D. Surgical treatment of diabetic foot ulcers: a review of forty-eight cases. *J Foot Surg* 23:102-111, 1984.
574. Mitchell ME. Lower extremity major amputations. In: *Diabetic Foot: Lower Extremity Arterial Disease and Limb Salvage*, pp 341-350, edited by AN Sidawy, Lippincott Williams & Wilkins, Philadelphia, 2006.
575. Sage RA, Pinzur M, Stuck R, Napolitano C. Amputations and Rehabilitation. In: *The Diabetic Foot: Medical and Surgical Management*, pp 317-344, edited by A Veves, J Giurini, and FW LoGerfo, Humana Press, Inc., Totowa, NJ, 2002.
576. Waters RL, Perry J, Antonelle D, Hislop H. Energy cost of walking of amputees: the influence of level of amputation. *J Bone Joint Surg* 58A:42-46, 1976.
577. Pinzur MS, Gold J, Schwartz D, Gross N. Energy demands for walking in dysvascular amputees as related to the level of amputation. *Orthopaedics* 15:1033-1073, 1992.
578. Calhoun JH, Mader JT, Sanford JP. Infection in the diabetic foot. *Hosp Pract (Off Ed)* 27(3A):81-84, 87-90, 99 passim, 1992.
579. Gordois A, Scuffham P, Shearer A, Oglesby A, Tobian JA. The health care costs of diabetic peripheral neuropathy in the US. *Diabetes Care* 26:1790-1795, 2003.



## NOTES